



This is a digital copy of a book that was preserved for generations on library shelves before it was carefully scanned by Google as part of a project to make the world's books discoverable online.

It has survived long enough for the copyright to expire and the book to enter the public domain. A public domain book is one that was never subject to copyright or whose legal copyright term has expired. Whether a book is in the public domain may vary country to country. Public domain books are our gateways to the past, representing a wealth of history, culture and knowledge that's often difficult to discover.

Marks, notations and other marginalia present in the original volume will appear in this file - a reminder of this book's long journey from the publisher to a library and finally to you.

### **Usage guidelines**

Google is proud to partner with libraries to digitize public domain materials and make them widely accessible. Public domain books belong to the public and we are merely their custodians. Nevertheless, this work is expensive, so in order to keep providing this resource, we have taken steps to prevent abuse by commercial parties, including placing technical restrictions on automated querying.


We also ask that you:

- + *Make non-commercial use of the files* We designed Google Book Search for use by individuals, and we request that you use these files for personal, non-commercial purposes.
- + *Refrain from automated querying* Do not send automated queries of any sort to Google's system: If you are conducting research on machine translation, optical character recognition or other areas where access to a large amount of text is helpful, please contact us. We encourage the use of public domain materials for these purposes and may be able to help.
- + *Maintain attribution* The Google "watermark" you see on each file is essential for informing people about this project and helping them find additional materials through Google Book Search. Please do not remove it.
- + *Keep it legal* Whatever your use, remember that you are responsible for ensuring that what you are doing is legal. Do not assume that just because we believe a book is in the public domain for users in the United States, that the work is also in the public domain for users in other countries. Whether a book is still in copyright varies from country to country, and we can't offer guidance on whether any specific use of any specific book is allowed. Please do not assume that a book's appearance in Google Book Search means it can be used in any manner anywhere in the world. Copyright infringement liability can be quite severe.

### **About Google Book Search**

Google's mission is to organize the world's information and to make it universally accessible and useful. Google Book Search helps readers discover the world's books while helping authors and publishers reach new audiences. You can search through the full text of this book on the web at <http://books.google.com/>

LANE MEDICAL LIBRARY STANFORD



2 45 0179 5784

# QUIZ-COMPENDS

## VISCERAL ANATOMY

DR POTTER.

E 28  
P 86  
1883

Dr. H. V. ...  
Property of  
Indianapolis, Ind.  
**ROBERTS' OSTROFF**

# Practice of Medicine.

**A NEW, ENLARGED EDITION. JUST READY.**

*Recommended as a Text-book at University of Pennsylvania, Long Island College Hospital, Yale and Harvard Colleges, Bishop's College, Montreal, University of Michigan, and over twenty other Medical Schools.*

**A HANDBOOK OF THE THEORY AND PRACTICE OF MEDICINE.** By **FREDERICK T. ROBERTS, M.D., M.R.C.P.**, Assistant Professor and Teacher of Clinical Medicine in University College Hospital, Assistant Physician in Brompton Consumptive Hospital. Third Edition. Octavo.

Price, in Cloth, \$3.00; Leather, \$6.00.

**RECOMMENDATIONS**

**LANE**

**MEDICAL**



**LIBRARY**

Gift  
Dr. Ostroff.

Our opinion of it is one of almost unqualified praise. The style is clear, and the amount of useful and, indeed, indispensable information which it contains is marvelous. We heartily recommend it to students, teachers, and practitioners."—*Boston Medical and Surgical Journal*.

"That Dr. Roberts' book is admirably fitted to supply the want of a good handbook of medicine, so much felt by every medical student, does not admit of a question."—*Students' Journal and Hospital Gazette*.

**P. BLAKISTON, SON & CO., Publishers and Booksellers,  
1012 WALNUT STREET, PHILADELPHIA.**

## MEDICAL BOOK DEALER.

**REFERENCE AND DOSE BOOK.**—By C. HENRI LEONARD, A. M., M. D. Professor of Medical and Surgical Diseases of Women, Michigan College of Medicine. Cloth, 16 mo., pages 112, post-paid 75 Cts.

This Book contains the doses of MORE remedies than any Dose Book published. Besides this, full tables of Antidotes to Poisons, Urinary Tests, and many pages of miscellaneous matter are given. It is used in every Medical College in the United States, and by Physicians and Druggists in every English-speaking country. OVER 30,000 COPIES HAVE BEEN SOLD.

"This is a book deserving of high praise; its completeness and freedom from errors, stamp it head and shoulders above the ordinary run of Dose Books with which our literature has, of late, been teeming."—SAN FRANCISCO LANCET.

**VEST POCKET ANATOMIST**, (founded upon Gray),

By THE SAME AUTHOR. Cloth 12 mo., pages 80, post-paid, 75 Cts.; paper covers, 50 cts.

Two Thousand copies of this little book have been sold to the Medical Students of London, England, alone. The TENTH THOUSAND has now been issued to the Student's in this country. This should be sufficient recommendation for it. It describes each Bone, Muscle, Artery Vein and Nerve, giving origin, insertion, course and points of interest of each, besides two classified tables.

"Brief, comprehensible, and TO THE POINT. In fact, it is Gray and Wilson in a short dress."—MEDICAL OBSERVER.

**STUDENT'S DOSE BOOK AND ANATOMIST**

**COMBINED.** By THE SAME AUTHOR. Cloth, 16 mo., pages 176, post-paid, \$1.00.

This volume contains the contents of both the ANATOMIST and DOSE BOOK. It is lighter and cheaper than if the volumes were bound singly.

**MANUAL OF BANDAGING.**—By THE SAME AUTHOR.

Cloth, octavo, pages 132; 110 illustrations; price, post-paid, \$1.50.

Besides chapters upon the minor points of the subject, it describes 30 Bandages of the Head; 10 of the Neck; 32 of the Upper Extremity; 56 of the Lower, and 24 of the Body. Some 2,000 copies have been sold.

THE ST. LOUIS MED. JOUR. says: "Every student should possess it; and as it is the most explicit and best illustrated English work of its kind, there will be few Physicians who will not prize its worth."

**THE HAIR: ITS DISEASES and TREATMENT.**—By THE SAME AUTHOR. Octavo, 320 pages, 116 Illustrations; post-paid \$2.00

It gives the Microscopical Anatomy of the Hair and Beard and Diagnosis, Cause and Treatment of all the Diseases to which they are liable, besides many pages of interesting anecdotes of its wonderful growth, and the manner of Dressing it by the Ancients.

THE CINCINNATI LANCET AND CLINIC says: "This volume is unique in medical literature, and although the author is the first to present the profession with a book on the subject, he has certainly accomplished the labor with the hand of a master."

**DAY BOOK, LEONARD'S PHYSICIANS' POK-**

**ET.**—Morocco, flap and pocket, price, \$1.00. Your name, town and year on the side, in gold, \$1.25.

All these books for sale by your Medical Book Dealer. They will also be sent postpaid on receipt of price by

*The Illustrated Medical Journal Co.,*

R  
H  
S  
M  
and  
Chi  
s M  
In  
t gratifi  
e.  
nt practi  
d Gyne.  
le practi-  
Medical  
science  
medical  
College  
hensive  
Byford  
ated by  
reatises  
arly be  
propri-  
tiology  
e, will  
se who

*Dr. H. Petrucci*

# RESUME OF OSTEOLOGY.

[From Leonard's Vest Pocket Anatomist, cloth, 75 cts.; paper, 50 cts. Dose Book and Anatomist Combined, \$1.00.]

Name of Bone.	Number of Articulations.	Number of Muscles attached.	Primary Developmental Centres.
Occipital	6	12	4
Parietal	5	1	1
Frontal	12	3	2
Temporal	5	14	4
Sphenoid	12	12	10
Ethmoid	15	none	3
Nasal	4	none	1
Maxillary Sup.	9	9	4
Lachrymal	4	1	1
Malar	4	5	1
Palate	7	4	1
Turbinated Inf.	4	none	1
Vomer	6	none	2
Maxillary Inf.	2	14	2
Hyoid	none	11	5
Sternum	16	10	6
Ribs (12)	24	19	34
Clavicle	3	6	2
Scapula	2	17	7
Humerus	3	24	7
Ulna	2	13	3
Radius	4	9	3
Scaphoid	5	none	1
Semilunar	5	none	1
Cuneiform	3	none	1
Pisiform	1	2	1
Trapezium	4	3	1
Trapezoid	4	1	1
Os Magnum	7	1	1
Unciform	5	2	1
Metacarpal (5)	19	18	10
Phalanges (14)	23	20	28
Vertebrae (24)	72	39	85
Sacrum	4	5	11
Coccyx	1	4	4
Innominate	3	33	3 and 5
Femur	3	23	5
Patella	1	4	sesamoid
Tibia	3	10	3
Fibula	2	9	3
Calcis	2	8	1
Cuboid	4	1	1
Astragalus	4	none	1
Scaphoid	4	1	1
Int. Cuneiform	4	2	1
Mid. Cuneiform	4	none	1
Ext. Cuneiform	6	2	1
Metatarsal (5)	21	13	10
Phalanges (14)	23	23	28
Malleus	1	3	1
Incus	2	none	1
Stapes	1	1	1

ALL THESE BOOKS FOR SALE BY  
 Callahan, DeLaid & Co., 20 West Washington St., Indianapolis.

CALL AND EXAMINE.

Both and examine and you will like it

# BYFORD'S Diseases of Women.

THIRD ENLARGED EDITION.

*Recommended as a text-book at Rush Medical College, Chicago; Woman's Medical College, Chicago; National Medical College, Washington, D. C., and other Medical Schools.*

THE PRACTICE OF MEDICINE AND SURGERY, APPLIED TO THE DISEASES AND ACCIDENTS INCIDENT TO WOMEN. By WM. H. BYFORD, A.M., M.D., author of "A Treatise on the Chronic Inflammation and Displacement of the Unimpregnated Uterus," and Professor of Obstetrics and Diseases of Women and Children in the Chicago Medical College, and in the Woman's Medical College, Chicago. Third Edition, Revised. In One Volume. Octavo. 164 Illustrations.

Price, Cloth, \$5.00; Leather, \$6.00.

## RECOMMENDATIONS.

"I have read with pleasure your book on Diseases of Women; it gratifies me to indorse its teachings."—*Prof. H. P. C. Wilson, Jr., Baltimore.*

"I am well acquainted with the author, and regard him an excellent practitioner and teacher."—*Dr. J. A. Ireland, Professor of Obstetrics and Gynecology, Louisville Medical College.*

"It is much improved and is still more what it always was, a valuable practical assistant to the practitioner."—*Prof. Henry G. Landis, Starling Medical College, Columbus.*

"I find, from its being so well brought up to the present state of the science it treats of, that it is particularly adapted to the requirements of the medical student."—*J. Fred Prioleau, M. D., Professor of Gynecology, Medical College of South Carolina, Charleston.*

"The author has presented to the profession a concise and comprehensive treatise on the subject of diseases of females. We congratulate Dr. Byford upon his success, and feel satisfied that the effort will be duly appreciated by those whom the work is intended to instruct. It is one of the best treatises on the subject ever submitted to the American profession, and will early be acknowledged as such. It is well written, and where necessary, is appropriately illustrated."—*Medical and Surgical Reporter, Philadelphia.*

"The present work being particularly of use where questions of etiology and general treatment are concerned. \* \* \* This volume, hence, will commend itself both to those who possess former editions and to those who do not. It cannot fail to be useful to many, and will certainly prove interesting to all."—*The American Journal of Obstetrics.*

"These important topics are all handled vigorously and practically. The work cannot fail to be in great demand, and to exert a material influence on clinical practice."—*New York Medical Journal.*

P. BLAKISTON, SON & CO., Publishers and Booksellers.  
1012 WALNUT STREET, PHILADELPHIA.

1881 - January - 1886  
G. M. B. - 1000 - 1012



A COMPEND  
OF  
VISCERAL ANATOMY.  

---

POTTER.



# ? QUIZ COMPENDS. ?

A NEW SERIES OF BOOKS FOR STUDENTS' USE IN

## QUIZ-CLASS AND EXAMINATION ROOMS.

☞ These Compendis are based on the most popular text-books, and the lectures of prominent professors.

☞ The Authors have had large experience as Quiz Masters and attachés of colleges, and are well acquainted with the wants of students.

☞ They are arranged in the most approved form, thorough and concise, with illustrations whenever they can be used to advantage.

☞ Can be used by students of *any* college.

☞ They contain information nowhere else collected in such a condensed, practical shape.

☞ Size is such that they may be easily carried in the pocket, and the price is low.

☞ They will be found very serviceable to physicians, as remembrancers.

### LIST OF VOLUMES.

**No. 1. ANATOMY.** By SAMUEL O. L. POTTER, M.D. 63 Illustrations. *Now ready.*

**No. 2. PRACTICE, Part I.** By DAN'L E. HUGHES, M.D., Demonstrator of Clinical Medicine, Jefferson College, Philadelphia. *Now ready.*

**No. 3. PRACTICE, Part II.** Same author. *Now ready.*

**No. 4. PHYSIOLOGY.** By A. P. BRUBAKER, M.D., Demonstrator of Physiology, Jefferson College, Philadelphia. *Now ready.*

**No. 5. OBSTETRICS.** By HENRY G. LANDIS, M.D., Professor of Obstetrics and Diseases of Women and Children, Starling Medical College, Columbus, Ohio. Illustrated. *Now ready.*

**No. 6. MATERIA MEDICA.** By SAMUEL O. L. POTTER, M.D. *Now Ready.*

**No. 7. CHEMISTRY.** By G. MASON WARD, M.D., Demonstrator of Chemistry, Jefferson College, Philadelphia. *Now ready.*

**No. 8. VISCERAL ANATOMY.** By SAMUEL O. L. POTTER, M.D. With illustrations.

**No. 9. SURGERY.** By ORVILLE HORWITZ, B.S., M.D. With numerous Illustrations.

Others in preparation.

Price, each, in Cloth, \$1.00.

Interleaved Edition, for taking Notes, \$1.25.

P. BLAKISTON, SON & CO., Publishers and Booksellers,  
1012 WALNUT STREET, PHILADELPHIA.

☞ Complete stock of Medical, Dental, Pharmaceutical and Scientific Books. Catalogues free.

? QUIZ-COMPENDS. ? No. 8.

---

A COMPEND  
OF  
VISCERAL ANATOMY

ESPECIALLY ADAPTED TO THE USE OF MEDICAL STUDENTS.

BY

SAMUEL O. L. POTTER, M.A., M.D.,

A. A. SURGEON, U. S. ARMY.

AUTHOR OF "A COMPEND OF HUMAN ANATOMY;" "A COMPEND OF MATERIA  
MEDICA AND THERAPEUTICS;" "AN INDEX OF COMPARATIVE THERAPEUTICS;"  
AND OF THE LEA PRIZE ESSAY OF JEFFERSON MEDICAL COLLEGE, ON  
"DYSALALIA, A STUDY OF SPEECH AND ITS DEFECTS."

---

WITH FORTY-ONE ILLUSTRATIONS.

PHILADELPHIA:  
P. BLAKISTON, SON & CO.,  
No. 1012 WALNUT STREET.  
1883.

TO THE MEMORY OF  
AN AMERICAN SURGEON AND ANATOMIST,  
WHOSE FAME IS RECOGNIZED THROUGHOUT  
THE WHOLE CIVILIZED WORLD,  
JOSEPH PANCOAST,  
LATE PROFESSOR OF ANATOMY IN JEFFERSON MEDICAL COLLEGE,  
AND TO  
WILLIAM H. PANCOAST,  
PROFESSOR OF ANATOMY IN JEFFERSON MEDICAL COLLEGE,  
THE TALENTED AND COURTEOUS  
REPRESENTATIVE OF A GREAT NAME,  
WHOSE ENTHUSIASTIC TEACHINGS NO LESS THAN  
HIS GENIAL SALUTATIONS ARE  
TREASURED IN LOVING REMEMBRANCE  
BY  
EVERY STUDENT WHO HAS HEARD HIM,  
THESE COMPENDS OF HUMAN ANATOMY ARE  
AFFECTIONATELY DEDICATED.

YASSEL: 1883

P86

1883

## PREFACE.

---

This Compend is a continuation of "Questions on Human Anatomy," and, like the latter, is chiefly based on Gray; though in the preparation of both volumes I have freely consulted Quain and other recognized authorities. While striving to carry out the object of this series in furnishing the medical student with a condensed manual of Anatomy, I have endeavored, from a strong conviction of the importance of the subject, to make these volumes deserving of the first rank among their kind. Believing that a judicious condensation, which does not slight the essential points of the subjects treated, cannot fail being of benefit in any department of science, I commit these Compend to the teachers and students of Anatomy, in the hope that they may be found worthy of place alongside the more exhaustive and exhausting text-books.

S. O. L. P.

FORT DOUGLAS, SALT LAKE CITY, UTAH, August, 1883.

99781



## TABLE OF CONTENTS.

	PAGE
<b>DIGESTIVE ORGANS.....</b>	9
ALIMENTARY CANAL.....	9
TEETH.....	9
STRUCTURE.....	10
DEVELOPMENT.....	11
MOUTH.....	12
PALATE.....	12
TONSILS.....	12
SALIVARY GLANDS.....	13
TONGUE.....	13
PHARYNX.....	14
ESOPHAGUS.....	16
STOMACH.....	16
SMALL INTESTINE.....	18
DUODENUM.....	18
JEJUNUM.....	19
ILEUM.....	19
LARGE INTESTINE.....	20
CÆCUM.....	20
APPENDIX VERMIFORMIS.....	20
COLON.....	20
RECTUM.....	20
LIVER.....	21
LIGAMENTS.....	22
FISSURES.....	22
LOBES.....	23
VESSELS.....	23
CAPSULE OF GLISSON.....	25
GALL-BLADDER.....	25
PANCREAS.....	26
DUCTLESS GLANDS.....	26
SPLEEN.....	27
THYROID GLAND.....	28
THYMUS GLAND.....	29
SUPRA-RENAL CAPSULES.....	29
ABDOMINAL CAVITY.....	30
BOUNDARIES.....	30
OPENINGS.....	30
REGIONS.....	31
PERITONEUM.....	32
FORAMEN OF WINSLOW.....	32
OMENTA.....	32
MESENTERIES.....	33
<b>ORGANS OF VOICE AND RESPIRATION.....</b>	34
LARYNX.....	34
TRACHEA AND BRONCHI.....	39
LUNGS.....	40
PLEURÆ.....	43
MEDIASTINUM.....	43
<b>URINARY ORGANS.....</b>	44
KIDNEYS.....	44
URETERS.....	46
BLADDER.....	47
MALE URETHRA.....	48
FEMALE URETHRA.....	48

	PAGE
<b>MALE GENERATIVE ORGANS</b> .....	50
PROSTATE GLAND.....	50
COWPER'S GLANDS.....	51
PENIS.....	51
TESTES AND APPENDAGES.....	53
DESCENT OF THE TESTES.....	55
<b>FEMALE ORGANS OF GENERATION</b> .....	56
VULVA.....	56
VAGINA.....	57
UTERUS AND APPENDAGES.....	57
FALLOPIAN TUBES.....	59
OVARIES.....	60
PAROVARIUM.....	61
MAMMÆ.....	61
<b>ORGANS OF SENSE</b> .....	62
SKIN AND ITS APPENDAGES.....	62
TONGUE.....	64
NOSE.....	65
SCHNEIDERIAN MEMBRANE.....	65
EYE.....	66
SCLEROTIC AND CORNEA.....	68
UVEAL TRACT.....	69
RETINA.....	71
HUMORS.....	73
OPTIC NERVE AND COMMISSURE.....	77
APPENDAGES OF THE EYE.....	78
EAR.....	81
EXTERNAL EAR.....	81
MEMBRANA TYMPANI.....	83
TYMPANUM.....	84
EUSTACHIAN TUBE.....	87
INTERNAL EAR.....	88
<b>HERNIA</b> .....	95
INGUINAL HERNIA.....	95
COVERINGS.....	96
FEMORAL HERNIA.....	97
COVERINGS.....	98
<b>PERINEUM</b> .....	98
MALE PERINEUM.....	99
LITHOTOMY.....	100
FEMALE PERINEUM.....	101

# A COMPEND OF VISCERAL ANATOMY.

---

**What is a Viscus?** *Viscus, gen. visceris, pl. viscera*, is a term which is applied to any internal organ of the body. *The viscera* are the organs contained in the three great cavities—cranium, thorax and abdomen—with their appendages. Of these the Heart and Brain have been described with the circulatory and nervous systems respectively. [See COMPEND OF ANATOMY, pages 99, 120.]

## THE DIGESTIVE ORGANS.

**What is the Alimentary Canal?** A musculo-membranous tube, from 25 to 30 feet in length, extending from the mouth to the anus, lined throughout with mucous membrane, furnished with several accessory organs, and performing the functions of ingestion, digestion, and egestion.

**Name its Subdivisions.** They are the Mouth, Pharynx, Œsophagus, Stomach, Small Intestine (duodenum, jejunum, and ileum) and Large Intestine (cæcum, colon and rectum). The first three lie above the diaphragm, the rest below it.

**Name the Accessory Organs of Digestion.** They are—the Teeth, Salivary glands (parotid, sub maxillary, sub-lingual), Liver, Pancreas and Spleen.

## THE TEETH.

**What are the Teeth?** They are 32 organs of digestion (20 temporary, or milk-teeth), situated one-half in each jaw, imbedded in the alveolar processes, and partly surrounded by the *gums*, which are composed of fibrous tissue and covered with mucous membrane. In each half of each jaw there are—

*Temporary Teeth* (5)—2 Incisors, 1 Canine, 2 Milk-molars.

*Permanent Teeth* (8)—2 Incisors, 1 Canine, 2 Bicuspids, 3 Molars.



**What are their general Characteristics?** Each tooth presents a—*Crown, or Body*,—the part seen projecting above the gum.

*Neck*,—the constricted portion between the crown and the fang.

*Fang, or Root*,—imbedded in the alveolus; and surrounded by the periodontal membrane or periosteum lining the alveolus.

*Pulp-cavity*,—in the interior, opening at the apex of the fang for the entrance of vessels and nerves.

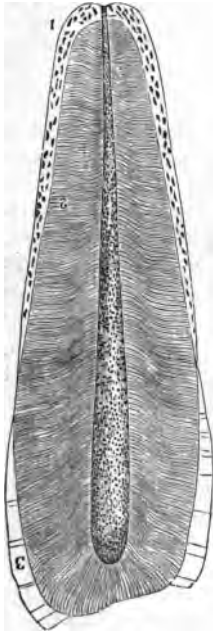
**What are the Characteristics of each class of Teeth?**

*Incisors, or Cutters*,—Crown chisel-shaped, bevelled posteriorly. Fang single, long, thickest antero-posteriorly.

*Canines, or Tearers*,—Crown thick and conical. Fang longest and thickest of all the teeth, forming a projection on the alveolar arch. The 2 upper canines are the “eye-teeth.”

*Bicuspids*,—Crown has 2 cusps. Fang single but grooved deeply, showing a marked tendency to bifurcate.

FIG. 1.



*Molars, or Grinders*,—Crown large, low, and cuboid in shape, has 4 cusps on upper molars, 5 on the lower ones. Fangs multiple, usually 3 on the first two upper molars, 2 on the first two lower ones; the third molar of either jaw, having but one fang, is called the “wisdom-tooth,” and is the smallest of the three.

The 2d or 3d Temporary Molar is larger than the first.

**Describe the Structure of a Tooth.** Each consists of—

*Dentine or Ivory*,<sup>2</sup>—composed of tubules surrounded by the inter-tubular tissue or Matrix, and opening into the pulp cavity. It resembles compact bone in appearance and in composition, consisting of 28 parts Animal matter and 72 Earthy matter. The *Tubules* are delicate wavy canals, diameter about  $\frac{1}{4500}$  of an inch, which branch outwardly and anastomose with each other, forming concentric shadings or *Schreyer's Lines*.

*Enamel*,<sup>3</sup>—covers the crown; consists of very dense tissue, which contains but  $3\frac{1}{2}$  per cent. of animal matter. It is covered by a very

delicate epithelial cuticle, *Nasmyth's Membrane*, which when intact withstands the action of acids.

*Crusta Petrosa or Cement*,<sup>1</sup>—the enamel of the fang; is a layer of true bony tissue, containing lacunæ, canaliculi, and Haversian canals.

*Pulp*,—fills the pulp-cavity and is prolonged into the dental tubules; is soft, vascular, and sensitive; and consists of connective and fibrous tissue, nucleated cells, blood-vessels and nerves. The cells are caudate and anastomose with each other, those situated superficially being termed *Odontoblasts*.

**What Arteries and Nerves supply the Teeth?** *The Arteries* are derived from the inferior dental, and from the alveolar and infraorbital branches of the internal maxillary. *The Nerves* are derived from the inferior dental branch of the inferior maxillary division of the 5th, and also from the anterior and posterior dental branches of its superior maxillary division.

**When do the Temporary Teeth appear?** Their eruption begins about the 7th month after birth, with the central incisors, and ends with the appearance of the second molars, about the age of 2 years. The lower teeth slightly antedate the upper.

**When do the Permanent Teeth appear?** The first molars appear about the end of the 6th year, followed by the incisors about the 7th or 8th year, the bicuspid from the 9th to the 10th year, the canines about the 11th or 12th year, the second molars from the 12th to the 13th year, and the third molars from the 17th to the 25th year. Those of the lower jaw are slightly in advance of the corresponding upper ones.

**What is the greatest Number of Teeth at one time in the jaws, and when?** Forty-eight, namely, all the temporary and permanent teeth except the third molars,—occurring between the 5th and 7th years of age.

**Describe the Development of the Teeth.** They arise from the mucous membrane covering the maxillary arches, in which, about the 6th foetal week, appears a depression, *the primitive dental groove*, from the floor of which arise papillæ of mucous membrane to form the pulp of the milk-teeth.

In the *Follicular Stage*, membranous septa form across the groove, and its margins become thick and prominent.

*The Saccular Stage* extends from the 13th week to the 16th, and is marked first by the projection of the papillæ from the follicles, next by the growth of the follicular margins, the formation of processes or *opercula* thereon, which meet and close in the papillæ; and finally by the closing

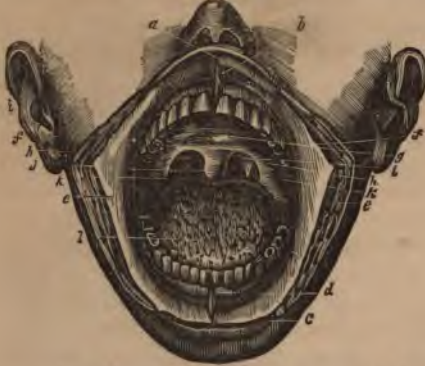in of the dental groove by the union of its margins. A *Cavity of Reserve* for each tooth is then formed by the closure of the secondary dental groove, from the floor of which another papilla arises to form the germ of the permanent tooth.

The dental pulps now take the forms of teeth, a thin lamina of dentine appears and increases from without inwards, the enamel organ and membrane are formed, and when calcification has advanced sufficiently, the pressure of the teeth causes the absorption of the gum above them, the septa ossify and the eruption of the teeth occurs. *The Cement* is formed from the periodontal membrane, at a later period of life.

### THE MOUTH.

**Describe the Mouth.** It is an oval cavity formed by the lips, cheeks, jaws, palate and tongue, forming the superior portion of the alimentary canal, and opening posteriorly into the pharynx by the fauces. It presents the

FIG. 2.



teeth (already described), the tongue *l* (to be described), and also the—

*Hard Palate*, formed by the palate processes of the superior maxillary and palate bones, and covered with mucous membrane; forms the roof of the mouth.

*Soft Palate*, formed by 5 muscles on each side, viz.—the levator palati, tensor palati,

palato-glossus, palato-pharyngeus, and the azygos uvulæ;—the latter forming with its fellow the *Uvula*, *f* a descending muscular projection.

*Anterior Pillars of the Fauces*, *h*—arch downwards and forwards to the base of the tongue, and contain the palato-glossi muscles.

*Posterior Pillars of the Fauces*, *i*—arch downwards and backwards to the sides of the pharynx, and contain the palato-pharyngei muscles.

*Isthmus Faucium*,—the space bounded by the pillars, the free border of the palate, and the base of the tongue.

*Tonsils*, *k*—are small, elongated, glandular bodies, situated one on each side of the fauces, between the anterior and posterior pillars. Each

has 12 or 15 openings on its surface, leading to follicular depressions within the gland, and lies close to the internal carotid artery.

*Openings of Steno's Ducts, f*—from the parotid glands, are situated internally on the cheeks, opposite the 2d upper molar teeth.

*Openings of Wharton's Ducts,*—from the sub-maxillary glands, at each side of the frenum of the tongue.<sup>d</sup>

*Openings of the Ducts of Rivinus,*—8 to 18 on each side, from the sub-lingual glands near the frenum of the tongue.<sup>d</sup> The longest is the *Duct of Bartholine*.

FIG. 3.



**Where are the Salivary Glands?** The *Parotid Gland*<sup>1</sup> lies below and in front of the external ear,—the *Sub-maxillary*<sup>3</sup> and *Sub-lingual*<sup>5</sup> Glands lie in the corresponding fossæ on the inner surface of the inferior maxillary bone.

**Describe the Tongue.** The tongue consists of extrinsic and intrinsic muscles, a hyo-glossal and a mucous membrane, a median fibrous septum, vessels and nerves. Its *base* is attached to the hyoid bone, the epiglottis, the soft palate and the pharynx. Its *under surface* is attached to the hyoid bone and the inferior maxillary. Its mucous membrane is reflected over the floor of the mouth to the inner surface of the gums, forming in front a fold, the *frenum*.

The tongue presents—

*Filiform Papillæ*, along its sides, closely packed in rows.

*Fungiform Papillæ*, scattered over the anterior two-thirds of its dorsum.

*Circumvallate Papillæ*, 7 to 12 in number, in two rows, forming a V at the base of the tongue, meeting at the *Foramen Cæcum*, which contains the central papilla.

*Follicular Glands*, posteriorly to the circumvallate papillæ.

*Racemose Glands*, over the dorsum, sides, and under surface. Beneath the tip they form two small oblong masses.

*Extrinsic Muscles*, are the stylo-, hyo-, genio-hyo-, and palato-glossus muscles.

*Intrinsic Muscles*, are the several fibres of the lingualis muscle,—superior, inferior, transverse and perpendicular.

**Name the Arteries of the Tongue.** They are the—

*Lingual*,—branch of the external carotid, with its branches, the—

Dorsalis linguae.                      Sub lingual.                      Ranine.

*Sub-mental*,—branch of the facial, anastomoses with the sub-lingual.

*Ascending Pharyngeal*,—branch of external carotid, sends some small branches to the pharynx and tongue.

**What Nerves are distributed to the Tongue?** The—

*Gustatory Branch of the 5th*,—to the mucous membrane of the sides and anterior two-thirds of the tongue, endowing it with general sensibility.

*Chorda Tympani Branch of the 7th*,—joins the gustatory, and is distributed to the same region, being the nerve of taste for the anterior two-thirds of the tongue.

*Lingual Branches of the 9th, or Glosso-pharyngeal*,—to the mucous membrane of the base and sides of the tongue, being the nerve of taste for its posterior third.

*Hypoglossal, or 12th*,—to the intrinsic and extrinsic muscles of the tongue, being its nerve of motion.

*Superior Laryngeal Branch of the 10th, or Pneumogastric*,—sends a few fibres to the base of the tongue from its internal branch.

**What special Anatomical Features are presented by the Mouth?**

They are as follows, viz.—the—

*Hamular Process of the Sphenoid Bone*,—may be felt behind the last upper molar tooth; also the *Internal Pterygoid Plate*, and part of the *Pterygoid Fossa*.

*Coronoid Process*,—of the lower jaw, its anterior border.

*Posterior Palatine Artery*,—at inner side of the last upper molar, and in front of the hamular process.

*Gustatory Nerve*,—very near the last lower molar.

*Pterygo maxillary Ligament*,—felt as a fold posteriorly to the last lower molar tooth.

## THE PHARYNX.

**Describe the Pharynx.** It is a conical, musculo-membranous bag, about  $4\frac{1}{2}$  inches long, hung base up, from the basilar process of the occipital bone, and extending to the lower border of the cricoid cartilage posteriorly, or the 5th cervical vertebra, where it becomes continuous with the œsophagus.<sup>5</sup> It forms the part of the alimentary canal which lies behind the mouth, being incomplete in front.

**What are its Relations ?** It is connected with—

*Posteriorly*,—the longus colli and recti capitis antici muscles, and by loose areolar tissue to the first 5 cervical vertebrae.

*Laterally*,—the styloid processes and their muscles, the pterygoid muscles, the internal carotid arteries, the internal jugular vein, the 8th, 9th, and the sympathetic nerves.

*Near its apex*,—the lobes of the thyroid gland, the common carotid and lingual arteries, the sterno-hyoid muscle, and the lingual nerves.

**What are its anterior Attachments ?**

The internal pterygoid plate, pterygo-maxillary ligament, lower jaw, base of the tongue, cornua of the hyoid bone, stylo-hyoid ligament, thyroid and cricoid cartilages of the larynx.

**Name the Openings into the Pharynx.**

They are 7, viz.—

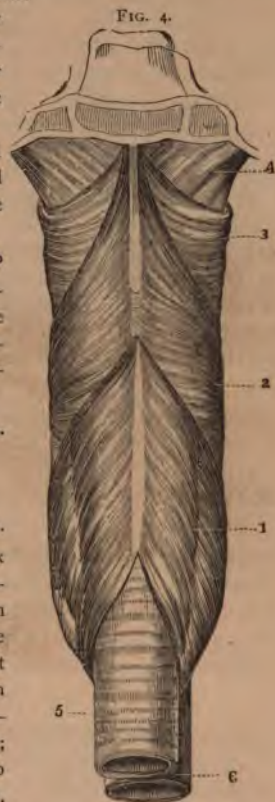2 Posterior nares.	Mouth.
2 Eustachian tubes.	Larynx.
	Oesophagus.

**Describe its Structure.** The pharynx

is composed of 3 coats,—a mucous, a muscular and a fibrous, the latter lying between the other two, and sometimes called the *pharyngeal aponeurosis*. The mucous coat is covered with ciliated columnar epithelium above the level of the floor of the nares,—below that level by squamous epithelium; and contains simple follicular glands, also compound follicular and racemose glands, the latter being most numerous in its upper part, between the two Eustachian tubes.

**Name its Muscles, Arteries, and Nerves.** Its—

*Muscles*, 5,—are the Superior, Middle and Inferior Constrictors, Stylo-pharyngeus, and Palato-pharyngeus. [See COMPEND OF ANATOMY, pages 73, 74.]



*Arteries* number 4, as follows,—

Superior thyroid branches.	} Branches of the External carotid.
Ascending pharyngeal.	
Pterygo-palatine.	} Branches of the Internal maxillary.
Descending palatine.	

*Nerves*,—branches of the pharyngeal plexus, which is formed by the pharyngeal branches of the pneumogastric, glosso-pharyngeal, superior laryngeal, and superior cervical ganglion of the sympathetic.

### THE ŒSOPHAGUS.

**Describe the Œsophagus.** It is a musculo-membranous tube, about 9 inches long, extending from the 5th cervical vertebra and the lower border of the cricoid cartilage of the larynx, through its opening in the diaphragm, to the cardiac orifice of the stomach, opposite the 9th dorsal vertebra, where it terminates. It lies in the neck, between the trachea and the vertebral column, resting in part on the longus colli muscle; then inclining to the left side it reaches the posterior mediastinum behind the left bronchus.

**What is its Structure?** The œsophagus has 3 coats, a—

*Mucous*,—in thick longitudinal folds; containing compound racemose glands.

*Cellular*,—connecting the other two coats, and containing the œsophageal vessels.

*Muscular*,—having longitudinal fibres externally, and circular fibres internally.

**Name its Vessels and Nerves.** The œsophageal—

*Arteries*, are chiefly branches from the thoracic aorta.

*Veins*, empty into the vena azygos minor.

*Nerves*, are branches of the pneumogastric and the cervical sympathetic, forming the œsophageal plexus.

### THE STOMACH.

**Describe the Stomach.** It is the principal organ of digestion, pyriform in shape, of musculo-membranous structure, about 12 inches long by 4 inches in average diameter, held in position by the lesser omentum, and situated diagonally across the upper abdomen, in the epigastric and right and left hypochondriac regions, above the transverse colon, below the liver and diaphragm. It presents for examination a—

*Fundus or Splenic End*,—is connected to the spleen by the gastro-splenic omentum.

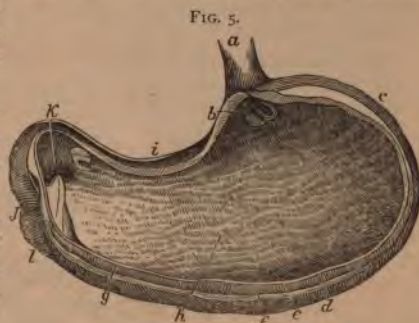*Pylorus or Lesser End*,—lies in contact with the anterior wall of the abdomen, the under surface of the liver, and the neck of the gall-bladder.

*Greater Curvature, d*—is convex, and is connected to the colon by the gastro-colic omentum.

*Lesser Curvature, i*—is concave, and connected to the liver by the gastro-hepatic omentum, and to the diaphragm by the gastro-phrenic ligament.

*Oesophageal Orifice, b*—is situated between the fundus and the lesser curvature.

*Pyloric Orifice, k*—opens into the duodenum, *l* and is guarded by the circular muscular fibres of the pylorus.



**What is its Structure?** The Stomach has 3 coats, a—

*Mucous Coat, g*—lined with columnar non-ciliated epithelium, covered with polygonal *alveoli*,  $\frac{1}{15}$  of an inch in diameter, containing the orifices of the *gastric follicles*. When the stomach is contracted the mucous membrane lies in longitudinal folds or *rugae, h* one of which forms a sort of valve at the pyloric orifice.

*Cellular or Sub-mucous Coat,*—contains the gastric vessels.

*Muscular Coat, f*—consists of longitudinal, circular and oblique fibres. *The longitudinal* are continuous with those of the oesophagus and small intestine, and are the most superficial. *The circular* lie deeper, and over the whole organ; they form a sphincter around the pyloric orifice. *The oblique fibres* lie deepest, forming two sets around the oesophageal opening, in continuation of the circular fibres of the oesophagus.

THE SEROUS INVESTMENT of the stomach is derived from the peritoneum, and covers the whole external surface, excepting the points where the gastro-splenic, greater and lesser omenta are attached. It is usually, but incorrectly, described as a fourth coat of the stomach.

**Describe the Gastric Glands.** They are of 3 kinds, the—

*Peptic Follicles,*—situated toward the splenic end; are tubules lined with columnar epithelium in their upper one-fourth, and being filled with nucleated cells in their deepest parts.

*Mucous Glands,*—situated near the pyloric end; are branched or sacculated, and lined throughout with columnar epithelium.



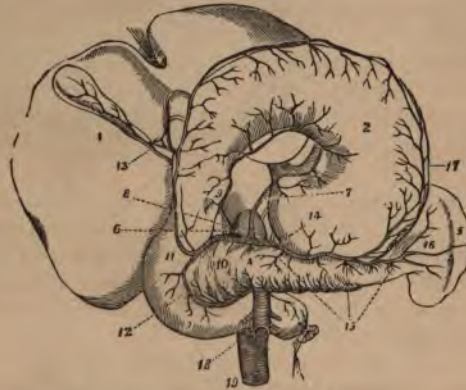
*Simple Solitary Glands* are found scattered along the lesser curvature, and near the pyloric end.

**Name the Vessels and Nerves of the Stomach.** Its—

*Arteries* are the—

Gastric, <sup>7</sup> Pyloric, <sup>9</sup>	} Branches of the Hepatic Artery. <sup>8</sup>
Right gastro-epiploic. <sup>11</sup>	
Left gastro-epiploic. <sup>17</sup>	} Branches of the Splenic Artery. <sup>14</sup>
Vasa brevía. <sup>16</sup>	

FIG. 6.



*Veins*, terminate in the splenic and portal veins.

*Nerves*, are terminal branches of the right and left pneumogastrics, and branches from the semilunar ganglia of the sympathetic, forming the *gastric plexus*.

#### THE SMALL INTESTINE.

**Describe the Small Intestine.** It is a convoluted, tubular, digestive organ, about 20 feet in length, held to the spinal column by the mesenteric portion of the peritoneum, and divided into 3 parts, the—

*Duodenum*,—about 12 fingers (10 inches) long, *ascends* for two and a half inches to the under surface of the liver and the neck of the gall-bladder,—*descends* for three and a half inches in front of the right kidney,—and passes transversely for 4 inches to the left, across the spinal column, to the left side of the second lumbar vertebra, where the superior mesenteric artery crosses its junction with the jejunum. The duodenum has no mesentery, is partially covered with peritoneum,

and surrounds the head of the pancreas. Into its descending portion open the ductus communis choledochus *f* and the pancreatic duct.

*Jejunum*,—about two-fifths of the rest of the small intestine, its coils lying around the umbilical region. It is named from the fact that it is usually found empty after death.

*Ileum*,—comprises the remainder of the small intestine, is named from its twisted course, lying below the umbilicus, and terminating in the right iliac fossa, at the ileo-cæcal valve, or valve of Bauhin.

**What Coats has the Small Intestine?** Three, a mucous, a sub-mucous or cellular, and a muscular coat. Its peritoneal investment is sometimes described as a fourth coat, but incorrectly. The—

*Mucous Membrane*,—is covered with columnar non-ciliated epithelium, and thrown into crescentic transverse folds, the *Valvula conniventes*, or valves of Kirkring. It also presents numerous vascular projections or *Villi*, formed of the basement membrane, epithelium, lacteals, a capillary plexus, granular corpuscles, and longitudinal muscular fibres.

*Cellular Coat*,—contains the vessels of the intestine, and connects the other two coats.

*Muscular Coat*,—consists of external longitudinal and internal circular fibres, the former being thinly distributed along the bowel.

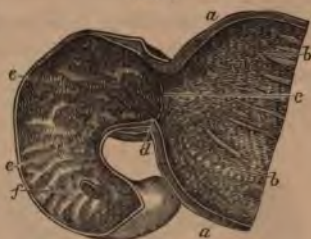**Describe the Glands of the Small Intestine.** The—

*Follicles of Lieberkühn*,—are minute tubular depressions, found all over the bowel and also in the stomach.

*Brunner's Glands*,—are small conglomerate glands, found only in the duodenum and the first part of the jejunum.

*Solitary Glands*,—are probably lymphatic organs, and are situated throughout the intestine, though most numerous at the lower portion of the ileum. They are agminated into some 20 or 30 oval patches, *Peyer's patches*, on the surface opposite to the mesenteric attachments, some of which are as much as 4 inches in length.

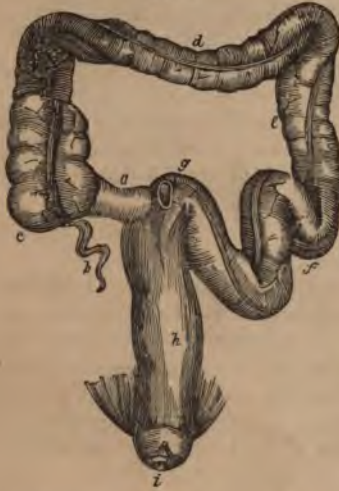FIG. 7.



## THE LARGE INTESTINE.

**Describe the Large Intestine.** It is about five feet long, of large calibre, sacculated, consists of the same coats as the small intestine, the mucous being smooth, and without villi, the muscular having its longitudinal fibres collected into 3 narrow bands, producing a pouching of the tube. It presents the following PARTS and *points*, viz.—

FIG. 8.



**CÆCUM, or Caput Cæcum Coli, c**

—a dilated blind pouch behind the entrance of the small intestine. *a* It is the beginning of the large intestine, lies in the right iliac fossa, and is two-thirds covered by peritoneum.

**Appendix Vermiformis, b**—a blind prolongation about 3 to 6 inches long, narrow and worm-like, directed backward and upward from the lower part of the cæcum, being retained by a fold of the peritoneum.

**Ileo-cæcal Valve, or Valve of Bauhin,**—guards the entrance of the small intestine, being formed by two crescentic folds of the mucous and cellular coats and circular muscular fibres,

each covered with villi on the side toward the ileum, but smooth on the cæcal side.

**ASCENDING COLON,**—extends upward to the under surface of the liver, where it forms the *hepatic flexure*.

**TRANSVERSE COLON, d**—crosses the abdominal cavity just below the liver, gall-bladder, stomach and spleen, to the left hypochondrium, where it terminates in the *splenic flexure*.

**DESCENDING COLON, e**—passes downward in front of the left kidney to the left iliac fossa, where it forms the—

*Sigmoid Flexure of the Colon, f*—curved like an *f*, first upward, then downward, extending from the crest of the left ileum to the left sacro-iliac synchondrosis.

**RECTUM, h**—from the last-named point to the anus; is 6 to 8 inches long, not sacculated, and straighter than the rest of the gut. It curves later-

ally to the middle of the sacrum, and backwards about an inch above its termination at the *Anus*, where it is distended into a pouch. This lower inch has no peritoneal investment.

*Appendices Epiploicæ*,—are small pouches of peritoneum containing fat, and found along the colon and part of the rectum. They are due to the incompleteness of the investment of the gut by peritoneum.

*Sphincters* of the rectum are 3,—the sphincter ani, internal sphincter, and sphincter tertius. (See ANATOMY, pages 83, 84.)

*Folds of Houston*,—three semilunar transverse folds, one in the upper part of the rectum on the right side, another about the middle on the left side, the third in front, opposite the base of the bladder.

**What Glands are found in the Large Intestine?** The *follicles of Lieberkühn* are more numerous here than elsewhere, also a few *solitary glands* and *Peyer's patches* in its upper portion. The glands of Brunner are absent, the villi and *valvulæ conniventes* are almost wanting.

**State the Principal Relations of each of the three parts of the Rectum.** They are as follows, viz.—

*1st or Upper Part* (4 inches),—lies on the left pyriformis muscle and the left sacral plexus; and to its left lie the left ureter and branches of the left internal iliac artery.

*2d or Middle Part* (3 inches),—in the male subject it lies just behind the trigonum vesicæ and the vesiculæ seminales, and close below the under surface of the prostate gland. In the female it is adherent to the centre portion of the posterior wall of the vagina.

*3d or Lower part* (1 inch),—is surrounded by the 3 sphincters and the levator ani muscle, and is separated by the perineum from the membranous portion and bulb of the urethra in the male, from the vagina in the female.

## THE LIVER.

**Describe the Liver.** It is the largest gland in the body, weighing from 3 to 4 pounds, measuring transversely about 12 inches, antero-posteriorly 6 inches, in greatest thickness 3 inches. It is situated in the right hypochondriac, epigastric and part of the left hypochondriac regions; has 5 fissures, 5 lobes, 5 ligaments, and 5 sets of vessels, and is invested by peritoneum, except for a small space at the attachment of the coronary ligament. It is also surrounded by a fibrous coat which is continuous at the transverse fissure with the capsule of Glisson. Its—

*Upper Surface*,—is convex, and in relation with the under surface of the diaphragm and 6 or 7 lower ribs.

*Under Surface* (Fig. 9),—is concave, covers the stomach, duodenum, hepatic flexure of colon, right kidney and supra-renal capsule, and is divided into 5 lobes by 5 fissures.

*Anterior Border, e*—sharp and notched opposite the fundus of the gall-bladder and the round and falciform ligaments. It corresponds to the lower border of the ribs and costal cartilages, descending a little lower during deep inspiration and in the upright posture.

*Posterior Border, d*—rounded, and deeply grooved (sometimes channelled) for the inferior vena cava.<sup>aa</sup>

**Describe the 5 Ligaments of the Liver.** Four are folds of peritoneum; one, the round ligament, is the obliterated umbilical vein and ductus venosus of the foetus. The—

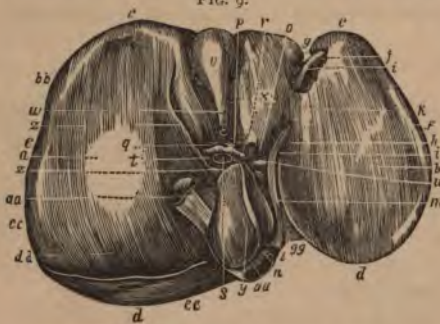
*Suspensory or Falciform Ligament, j*—called also the Broad and the Longitudinal ligament,—is a sickle-shaped double fold reflected over the round ligament, and is attached to the sheath of the right rectus muscle as low as the umbilicus, and to the diaphragm.

*Coronary Ligament, f*—is a double fold, containing firm areolar tissue in its interspace, and extending from the posterior border of the liver to the diaphragm.

*Lateral Ligaments, 2,*—are the triangular extremities of the coronary ligament.

*Round Ligament, i*—ascends in the free margin of the suspensory ligament from the umbilicus to the longitudinal fissure, in which it is continued to the vena cava.

**Describe the 5 Hepatic Fissures.** They are all situated on its under surface, and separate the 5 lobes one from another. They are the—



*Longitudinal Fissure, h*—its anterior two-thirds, in front of the transverse fissure is called the *umbilical fissure*, from containing the umbilical

vein; its posterior one-third is the *Fissure of the ductus venosus*.

*Transverse Fissure, v*—about 2 inches long, running from the longitudinal towards the right; and transmits the portal vein, hepatic artery, bile-duct, lymphatics and nerves, surrounded by the *Capsule of Glisson*.

*Fissure of the Gall-bladder, v*—on the right of the longitudinal fissure, and nearly parallel with it, extending backwards from the anterior border.

*Fissure for the Vena Cava*,—extends inward from the posterior border, where it joins the fissure for the ductus venosus: and gives exit to the hepatic veins which here join the vena cava. This fissure is occasionally a complete foramen.

**Describe the 5 Hepatic Lobes.** Three are mere lobules, formed from the right lobe by the smaller fissures. The—

*Right Lobe, a*—is much the largest, and presents the three small fissures and two depressions, one anteriorly for the colon, the other posteriorly for the kidney.

*Left Lobe, b*—is divided from the right by the longitudinal fissure, and rests upon the stomach.

*Lobulus Quadratus, x*—in front of the transverse fissure, and between the umbilical fissure and that for the gall-bladder.

*Lobulus Spigelii, y*—behind the transverse fissure, and between the fissure for the ductus venosus and that for the vena cava.

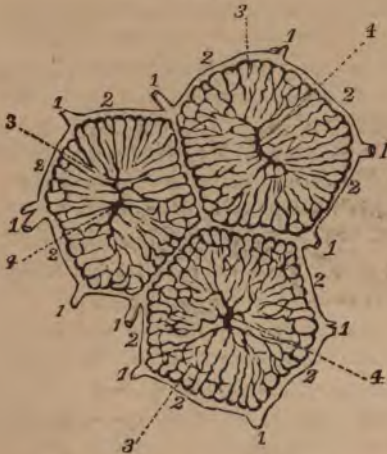*Lobulus Caudatus, z*—a connecting ridge from the lobulus Spigelii to the right lobe; it separates the transverse fissure from the fissure for the vena cava, and forms the roof of the foramen of Winslow.

**Describe the 5 Hepatic Vessels.** They are the—portal vein, hepatic artery, *g* hepatic duct, *h* and lymphatics, situated in the transverse fissure, and surrounded by the capsule of Glisson,—the hepatic veins in the fissure for the vena cava. The—

*Portal Vein, s*—formed by the superior and inferior mesenteric, splenic and gastric veins (all the main veins of the abdomen except the renal), is about 4 inches long. It enters the transverse fissure of the liver, where it divides into two branches, and these again divide and subdivide to ramify throughout the gland. Its branches are named the—

Right portal.	Inter-lobular veins. <sup>1</sup>	} Lobular Plexus.
Left portal.	Lobular veins. <sup>2</sup>	
Vaginal branches.	Intra-lobular veins. <sup>4</sup>	

FIG. 10.



*Hepatic Veins*,—are the continuations of the intra-lobular, beginning as the *sub-lobular veins* beneath each lobule, and entering the inferior vena cava in the fissure for that vessel.

*Hepatic Artery*, *q*—the nutrient vessel of the liver, arises from the coeliac axis, enters the transverse fissure, and divides into branches which supply the cellular tissue, the walls of the vessels, and the investing membranes of the liver, also forming

a plexus in each lobule which anastomoses with the terminal branches of the portal vein.

*Hepatic Duct*,—about  $1\frac{1}{2}$  inch long, is formed in the transverse fissure by the union of the two main *biliary ducts*, from the right and left lobes. It joins the cystic duct from the gall-bladder to form the ductus communis choledochus.

*Lymphatics*,—accompany the blood-vessels in two sets, a superficial and a deep one.

**What Nerves supply the Liver?** Branches of the hepatic plexus, which is formed by branches derived from the left pneumogastric, right phrenic and solar plexus.

**Describe the Structure of the Liver.** The substance of the liver is composed of numerous *lobules*,<sup>1</sup> of polygonal shape, and about  $\frac{1}{10}$  of an inch in diameter, clustered around the sub-lobular branches of the hepatic veins, and connected together by connective tissue,<sup>3</sup> blood vessels, ducts,<sup>2</sup> and lymphatics. Each lobule consists of—

*Hepatic Cells*,—each about the  $\frac{1}{1000}$  of an inch in diameter, having a nucleus and nucleolus, yellow coloring matter, glycogen granules, and oil-globules.

*Lobular Veins*,—forming a plexus in the lobule.

*Intra lobular Vein,*  
—in the centre of  
each lobule.

*Plexuses,*—of lym-  
phatics, nerves,  
and bile-ducts.

**What is the Cap-  
sule of Glisson?**

The areolar tissue which surrounds the hepatic vessels in the transverse fissure, and accompanies them in their course throughout the substance of the liver. It is continuous with the fibrous covering of the organ.

**How may the Portal Veins be distinguished from the Hepatic, on section of the Liver?** The portal veins remain closed, being surrounded by the capsule of Glisson. The hepatic veins gape open, being adherent to the liver substance.

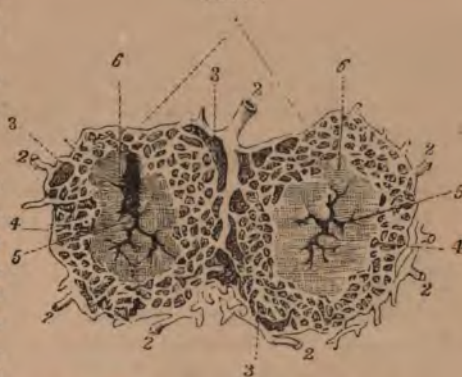**Describe the Gall-bladder.** It is a pear-shaped bag, 3 to 4 inches long, an inch in greatest diameter, holding from 8 to 12 fluid drachms, invested by peritoneum on its under surface and fundus, formed of a fibro-muscular and lined by a mucous coat, lying in a fissure on the under surface of the liver, close to its anterior border, and directed obliquely downwards, forwards, and to the right. Its—

*Fundus,*—touches the abdominal wall on a level with the tip of the 10th costal cartilage.

*Neck,*—coils twice upon itself, and empties into the *cystic duct*, which is about an inch long and joins with the hepatic duct to form the *ductus communis choledochus*.

**What is the Ductus Communis Choledochus?** A fibro-muscular tube, covered by peritoneum and lined with mucous membrane, about 3 inches in length, formed by the junction of the cystic and hepatic ducts, emptying its contents (bile) into the descending part of the duodenum at a point about 3 inches from the pyloric orifice of the stomach, generally in common with the duct of the pancreas.

FIG. 11.



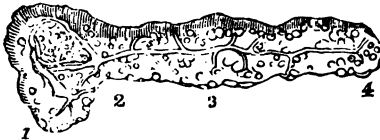


## THE PANCREAS.

**Describe the Pancreas.** The Pancreas is a racemose gland, about 7 inches long, of a greyish-white color, and situated behind the stomach and in front of the first lumbar vertebra. Its structure resembles that of the salivary glands, being composed of reddish-yellow lobules, united by cellular tissue, vessels and ducts, and ending in closed pouches surrounded by a capillary plexus. The—

*Pancreatic Duct, or Duct of Wirsung,*<sup>5</sup>—extends the whole length of the gland, and opens into the duodenum about 3 inches below the pylorus, by an orifice common to it and the ductus communis choledochus.

FIG. 12.



*Head, or Right Extremity,*<sup>1</sup>—is surrounded by the curve of the duodenum, the ductus communis choledochus and the pancreatico-duodenal arteries.

*Tail, or Left Extremity,*<sup>4</sup>—lies above the left kidney and in contact with the spleen.

*Body*<sup>2</sup>—is in relation *anteriorly* with the ascending layer of the transverse meso-colon, the posterior wall of the stomach and the transverse colon; *posteriorly* with the aorta, portal vein, inferior vena cava, splenic vein, origin of the superior mesenteric artery, crura of the diaphragm, left kidney and supra-renal capsule, and the left quadratus lumborum muscle.

*Arteries,*—are the pancreatica magna and pancreatice parvæ, brs. of the splenic; the pancreatico-duodenalis, br. of the hepatic; and the inferior pancreatico-duodenalis, br. of the superior mesenteric.

*Veins,*—open into the splenic and mesenteric veins.

*Nerves,*—from the solar plexus, forming a splenic plexus.

**What is the Lesser Pancreas?** A lobe of the head of the pancreas; sometimes detached therefrom and opening by a duct into the duodenum about an inch above the orifice of the pancreatic duct.

## THE DUCTLESS GLANDS.

**Name the so-called Ductless Glands.** They are the Spleen, Supra-renal Capsules, Thyroid and Thymus Glands. The first two are in the abdominal cavity, the thyroid gland is in the front of the trachea, and the thymus gland is in the anterior mediastinum of the thorax. These organs have no excretory ducts, and their functions are unknown.

## THE SPLEEN.

**Describe the Spleen.** The Spleen is a soft, spongy and very vascular organ, about 5 inches by 3 by 2, from 6 to 10 ounces in weight, and situated deeply in the left hypochondrium, embracing the cardiac end of the stomach, to which it is connected by the gastro-splenic omentum. Its—

*Outer Surface*,—is convex, corresponds to the 9th, 10th and 11th ribs, and is in relation with the inferior surface of the diaphragm.

*Inner Surface*,—is concave, and embraces the cardiac or splenic end of the stomach.

FIG. 13.

*Borders*,—the anterior is thin and often notched; the posterior is thick and lies on the left kidney.

*Suspensory Ligament*,—attaches the upper extremity to the diaphragm, and is a fold of peritoneum.

*Hilum*,—a vertical fissure about the middle of the concave surface. It is pierced by the vessels, lymphatics and nerves.

*Serous, or Peritoneal Coat*,—covers the whole organ, except at the attachments of the suspensory ligament and the gastro-splenic omentum.

*Fibro-elastic Coat, or Tunica Propria*,—is reflected at the hilum upon the vessels, and gives off numerous bands (*trabeculae*), which bound the lacunar spaces (*areolae*) of the organ.

*Malpighian Corpuscles*,—are lymphoid sphenoidal expansions of the outer coat of the small arteries, and average in diameter about the  $\frac{1}{80}$  of an inch. They are attached to the arterioles of the organ in groups of 6 or 8, and are usually pierced by an artery. Their reticulum is slender and open, densely filled with lymphoid corpuscles, and well supplied with capillaries. They have no capsule.

*Splenic Substance or Pulp*,—a soft, pulpy, brown-red mass, surrounding the Malpighian corpuscles, and contained in the areolae. It consists of a delicate network of connective-tissue corpuscles, containing pigment-granules (disintegrated blood-corpuscles), granular albuminous matter, nucleated and non-nucleated cells, and free nuclei, also red blood-corpuscles in every stage of metamorphosis. These are denominated the colored and colorless elements.

*Splenic Artery*,—is large and tortuous, and divides at the hilum into 5 or 6 branches, each supplying a segment of the organ, and terminating either directly in the venous radicles, or in the lacunar spaces.

*Splenic Vein*,—arises by radicles partly from the capillaries, partly from the lacunar spaces, and empties into the portal vein.



*Nerves*,—are derived from the semi-lunar ganglion of the solar plexus and the right pneumogastric, forming the splenic plexus.

### THE THYROID GLAND.

**Describe the Thyroid Gland.** It is a bi-lobed organ, about 3 inches in length, situated on the sides of the upper 2 or 3 rings of the trachea, and consisting of minute closed vesicles containing a yellow-colored fluid, surrounded by a dense plexus of capillaries, and connected together by areolar tissue. Its—

*Isthmus*,—connects the lower third of each lobe together, passing in front of the trachea. It is occasionally absent.

*Pyramid*,—is a third lobe, which sometimes arises from the left lobe, or from the left upper border of the isthmus.

*Levator Glandule Thyroideæ*,—are muscular bands occasionally found extending from the body of the hyoid bone to the isthmus of the gland or its pyramid.

**Name the Arteries of the Thyroid Gland.** They are very large, anastomose freely, and are the—

*Superior Thyroid*,—br. of the External Carotid, arising therefrom below the greater cornu of the hyoid bone, and giving off the following branches, viz.—

Muscular.	Hyoid.	Superior Laryngeal.
Glandular.	Superficial descending.	Crico-thyroid.

*Middle Thyroid, Artery of Neibauhr, or Arteria Thyroidea Ima*,—is occasionally found arising from the innominate artery or directly from the arch of the aorta, and passing upwards along the front of the trachea.

*Inferior Thyroid*, br. of Thyroid Axis, gives off—

Laryngeal branch.	(Esophageal branches.
Tracheal branches.	Ascending Cervical.

**What are the Veins and Nerves of the Thyroid Gland?** The *Veins* form a plexus in front of the gland and the trachea, giving rise to the—

<i>Superior Thyroid Vein.</i>	} open into the Internal Jugular.
<i>Middle Thyroid Vein.</i>	

*Inferior Thyroid Vein*, opens into the Innominate.

*Nerves*—are branches of the pneumogastric, and of the middle and inferior ganglia of the sympathetic.

## THE THYMUS GLAND.

**What is the Thymus Gland?** It is a temporary organ, attaining its full size about the age of 2 years, then being about 2 inches long,  $1\frac{1}{2}$  inch broad, 3 lines thick, and weighing about  $\frac{1}{2}$  ounce. It subsequently atrophies, and has almost disappeared at puberty. It is situated in the anterior mediastinum and the neck, behind the sternum and the sterno-hyoid and sterno-thyroid muscles, extending from the level of the 4th costal cartilage to the lower border of the thyroid gland. In the mediastinum it rests upon the pericardium, and is separated by the thoracic fascia from the arch of the aorta and the great vessels.

**Describe its Structure.** The Thymus Gland consists of two lateral lobes (sometimes a third), together forming a pyramidal mass. It is surrounded by a fibrous capsule and is divided by *trabeculae* into primary and secondary lobules, which consist of meshes of delicate retiform tissue closely packed with lymph-corpuscles, and pervaded with capillaries. The so-called *central cavity* and *primitive linear tube* are deceptive appearances of the multiplying cells in the interior of the gland.

**What are its Vessels and Nerves?** The arteries ramify on the surface of each lobule, having smaller twigs converging toward the centre.

*Arteries*,—from the internal mammary, superior and inferior thyroid, sub-clavian and carotid.

*Veins*,—open into the left innominate and the thyroid.

*Lymphatics*,—consist of intralobular and interlobular plexuses, and open into the anterior mediastinal glands.

*Nerves*,—are very minute and derived from the pneumogastric and the sympathetic.

## THE SUPRA-RENAL CAPSULES.

**What are the Supra-Renal Capsules?** They are two small crescentic-shaped bodies, situated one on each kidney. Each presents a small fissure or *hilum* anteriorly, from which its vein emerges, and consists of a—

*Fibrous Capsule*,—which is very thin, closely adherent, and sends numerous septa inward.

*Cortical Substance*,—composed of columnar and rounded cells, held together in layers by a fibrous stroma.

*Medullary Substance*,—is darker than the cortical portion, and pulpy. Consists of cells in groups, supported by a delicate stroma, and believed by some anatomists to be prolonged into nerve-fibres.

**What are their Relations?** Their bases rest on the upper front parts of the kidneys, their posterior surfaces on the crura of the diaphragm, about the level of the 10th dorsal vertebra. The—

*Anterior Surface*,—of the right capsule is covered by the liver; that of the left one by the spleen and pancreas.

*Superior Surface*,—of each is in relation internally with the great splanchnic nerve and semilunar ganglion.

**Name their Vessels and Nerves.** The *Lymphatics* of these bodies open into the lumbar glands, but are very imperfectly known. Their—

*Arteries*,—are the Supra-renal branches of the aorta, renal and inferior phrenic arteries, forming a dense capillary plexus in the cortical portion.

*Veins*,—of each open into a single trunk, the supra-renal vein, which on the right side of the body empties into the inferior vena cava, on the left side into the left renal vein.

*Nerves*,—are chiefly derived from the solar and renal plexuses, with some filaments from the phrenic and pneumogastric nerves, forming a complicated network in the medullary substance of the organ.

#### THE ABDOMINAL CAVITY.

**What is the Abdomen?** An oval cavity, situated between the thorax above and the pelvis below, invested by peritoneum internally, and containing the—

<i>Stomach.</i>	<i>Pancreas.</i>	<i>Abdominal Aorta.</i>
<i>Intestines.</i>	<i>Kidneys and Ureters.</i>	<i>Inferior Vena Cava.</i>
<i>Liver.</i>	<i>Supra-renal Capsules,</i>	<i>Receptaculum Chyli.</i>
<i>Gall-bladder.</i>	<i>Bladder, when distended.</i>	<i>Thoracic Duct.</i>
<i>Spleen.</i>	<i>Uterus, during pregnancy.</i>	<i>Solar Plexus, etc.</i>

**Name the Boundaries of the Abdomen.** *Above*, it is bounded by the diaphragm;—*below*, by the brim of the pelvis;—*posteriorly*, by the vertebral column, and the fasciæ covering the psoæ and quadrati lumborum muscles;—*anteriorly and laterally*, by the transversalis fascia, the lower ribs, and the venter of the ileum.

**What Openings are found in its walls?** They are the—

*Opening for the Vena Cava*,—in the diaphragm.

*Aortic*,—behind the diaphragm, for the aorta, vena azygos minor, the thoracic duct, and occasionally the left sympathetic nerve.

*Œsophageal*,—in the diaphragm, for the œsophagus and the pneumogastric nerves.

*Umbilicus*,—in the anterior wall, transmitting the umbilical vessels in the foetus.

*Internal Abdominal Ring*,—on each side  $\frac{1}{2}$  inch above Poupart's ligament; for the passage of the spermatic cord in the male, and the round ligament in the female.

*Femoral or Crural Ring*,—on each side just below Poupart's ligament; for the passage of the femoral vessels. This opening is closed by the septum crurale.

**Name the Regions of the Abdomen.** The Abdomen is divided into 9 regions, by 2 horizontal lines,—one between the cartilages of the 9th ribs, another between the crests of the ilia,—and 2 vertical lines from the cartilages of the 8th ribs to the centre of Poupart's ligament. The 9 regions thus formed are named the—

<i>Right Hypochondriac.</i>	<i>Epigastric.</i>	<i>Left Hypochondriac.</i>
<i>Right Lumbar.</i>	<i>Umbilical.</i>	<i>Left Lumbar.</i>
<i>Right Inguinal.</i>	<i>Hypogastric.</i>	<i>Left Inguinal.</i>

**What Parts are contained in each Region?**

*Right Hypochondriac*,—contains the right lobe of the liver, gall-bladder, duodenum, hepatic flexure of the colon, upper part of the right kidney, and the right supra-renal capsule.

*Epigastric*,—contains the right two-thirds of the stomach, left lobe and lobus Spigelii of the liver, hepatic vessels, celiac axis, solar plexus, pancreas, and parts of the aorta, inferior vena cava, vena azygos, and thoracic duct.

*Left Hypochondriac*,—contains the splenic end of the stomach, spleen, tail of the pancreas, splenic flexure of the colon, upper  $\frac{1}{2}$  of the left kidney and its supra-renal capsule.

*Right Lumbar*,—contains the ascending colon, lower half of the right kidney, and part of the small intestines.

*Umbilical*,—contains the transverse colon, transverse duodenum, part of the great omentum and mesentery, and part of the small intestines.

*Left Lumbar*,—contains the descending colon, lower half of the left kidney, and part of the small intestines.

*Right Inguinal*,—contains the right ureter, cæcum, appendix vermiformis, and the spermatic vessels of that side.

*Hypogastric*,—contains part of the small intestines, the bladder in children and when distended in adults, and the uterus during pregnancy.

*Left Inguinal*,—contains the left ureter and spermatic vessels, and the sigmoid flexure of the colon.

## THE PERITONEUM.

**What is the Peritoneum?** A serous membrane, forming a closed sac, its *parietal layer* lining the walls of the abdomen and pelvis, its *visceral layer* being reflected more or less completely over all the abdominal and pelvic viscera. Its free surface is covered with squamous epithelium, and is smooth, moist, and shining. Its attached surface is connected to the viscera and the parietes by the sub-peritoneal areolar tissue.

**Is the Peritoneum always a closed sac?** No! In the female it is continuous with the mucous lining of the Fallopian tubes, which at their free extremities open into its cavity.

**Name the Divisions of the Peritoneum.** The—

*Greater Sac*,—extends over the anterior two-thirds of the liver, behind and above the stomach, below, behind, and in front of the great omentum, and below the meso-colon.

*Lesser Sac, or Cavity of the Great Omentum*,—extends behind and below the liver and stomach, above the meso-colon, and within the great omentum.

**What is the Foramen of Winslow?** A constriction of the peritoneal cavity connecting the two sacs, situated behind the right free border of the gastro-hepatic or lesser omentum, and formed by the gastric and hepatic arteries as they curve around to the cœliac axis. Its boundaries are as follows, viz.—

*Anteriorly*,—the lesser omentum, containing the duodenum, hepatic artery, portal vein, and ductus communis choledochus.

*Posteriorly*,—the inferior vena cava, and the right crus of the diaphragm.

*Superiorly*,—the lobus caudatus of the liver.

*Inferiorly*,—the hepatic artery.

**What passes through the Foramen of Winslow?** Nothing.

**What are the Omenta or Epiplœa?** They are folds of peritoneum connecting the stomach with other organs, and are 3 in number, namely, the—

*Gastro-colic or Great Omentum*,<sup>14</sup>—consists of 4 layers of peritoneum, the most anterior and posterior of which belong to the greater sac, the two internal to the lesser sac. The two anterior layers descend from the stomach and the spleen, over the small intestines, and then ascend as the posterior layers, to enclose the transverse colon.

*Gastro-hepatic or Lesser Omentum*,—consists of 2 layers of peritoneum, the upper belonging to the greater sac, the lower to the lesser sac.

It extends from the transverse fissure of the liver to the lesser curvature of the stomach, and contains in its right free margin the—

Hepatic Artery.	Ductus Communis Choledochus.
Portal Vein.	First part of the Duodenum.
Lymphatics.	Hepatic Plexus.

*Gastro-splenic Omentum*,—connects the stomach with the spleen, and is continuous by its lower border with the great omentum. It contains the splenic vessels and the vasa brevia.

**What are the Mesos or Mesenteries?** Folds of peritoneum connecting the various parts of the intestinal canal (except the duodenum) to the abdominal walls. Each one contains the vessels of the part which it supports. They are the—

*Mesentery proper.*<sup>1 9</sup> *Meso-colon.*<sup>2 8</sup>  
*Meso-cæcum.* *Meso-rectum.*

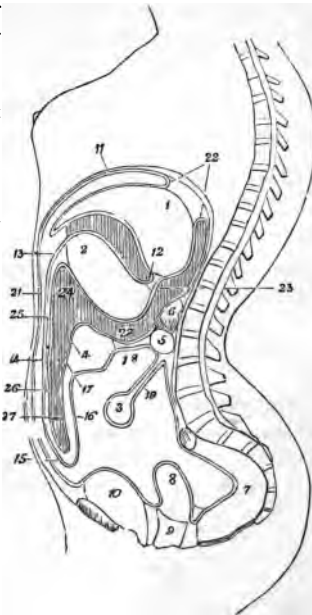
**What Ligaments are formed by the Peritoneum?** They are folds which support certain organs, viz.—

- 1 *Gastro-phrenic*,—from the stomach to the diaphragm.
- 4 *Hepatic*,—the longitudinal, coronary, and 2 lateral.
- 5 *Vesical*,—the false ligaments of the bladder.
- 6 *Uterine*,—2 vesico-uterine, 2 recto-uterine, and 2 lateral or broad ligaments.
- 1 *Splenic*,—the suspensory ligament of the spleen.

**Name the Viscera covered by Peritoneum.** They are the—

*Liver*<sup>1</sup> (almost wholly).  
*Stomach*<sup>2</sup> (almost wholly).  
*Spleen.*  
*Duodenum*<sup>5</sup> (first part).  
*Small Intestines.*<sup>8</sup>

FIG. 14.



*Transverse colon.*<sup>4</sup>  
*Sigmoid flexure.*  
*Rectum* (upper  $\frac{1}{3}$ ).  
*Ovaries.*  
*Uterus.*<sup>8</sup>



**Name the Viscera partially invested by Peritoneum.** The—

<i>Duodenum</i> <sup>5</sup> (descending and transverse portions).	<i>Descending Colon.</i>
<i>Cacum.</i>	<i>Rectum</i> <sup>7</sup> (middle third).
<i>Ascending Colon.</i>	<i>Vagina</i> <sup>9</sup> (upper part).
	<i>Bladder</i> <sup>10</sup> (posterior wall).

**What Viscera have no Peritoneal investment?** The—

<i>Rectum</i> <sup>7</sup> (lower third).	<i>Pancreas.</i> <sup>6</sup>
<i>Bladder</i> <sup>10</sup> (neck, base and anterior surface).	<i>Kidneys.</i>
	<i>Supra-renal Capsules.</i>
<i>Vagina</i> <sup>9</sup> (lower part).	

**What are the Appendices Epiploicæ?** Pouches of peritoneum situated along the colon and upper third of the rectum, and filled with fat.

## ORGANS OF VOICE AND RESPIRATION.

### THE LARYNX.

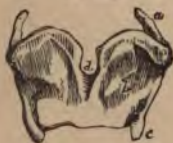**What is the Larynx?** A musculo-membranous-cartilaginous box placed between the trachea and the base of the tongue, and constituting the essential organ of voice.

**Name its Cartilages.** They are nine in number, 3 single and 3 in pairs, viz.—

<i>Thyroid Cartilage.</i>	<i>2 Arytenoid Cartilages.</i>
<i>Cricoid Cartilage.</i>	<i>2 Cuneiform Cartilages.</i>
<i>Epiglottis.</i>	<i>2 Cornicula Laryngis.</i>

**Describe the Thyroid Cartilage.** The thyroid or shield-like cartilage consists of two *alæ* or wings,<sup>b</sup> united in front at an acute angle, the highest portion of its front being called the *pomum Adami*, Adam's apple. Its—  
*Inner Surface*,—gives attachment to the true and false vocal chords, the epiglottis, thyro-arytenoid and thyro-epiglottidean muscles, and the thyro-epiglottic ligament.

FIG. 15.



*Outer Surface*,—affords attachment to the sternothyroid, thyro-hyoid and inferior constrictor muscles; the first two being attached along its oblique ridge.

*Upper Border*,—is curved irregularly, and gives attachment to the thyro-hyoid membrane.

*Lower Border*,—gives attachment to the crico-thyroid membrane in the median line, and on each side to the crico-thyroid muscle.

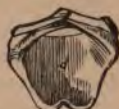*Posterior Border* of each wing ends above and below in *cornu* (horns), and gives attachment to the stylo- and palato-pharyngeus muscles.

*Superior Cornua* of each side affords attachment to the thyro-hyoid ligament.

*Inferior Cornua*—articulate with the cricoid cartilage by a small oval facet on each.

**Describe the Cricoid Cartilage.** The cricoid, or ring-like cartilage, is placed below the thyroid, with its narrow part to the front. It has on each side 2 *articular facets*, one on the upper margin posteriorly for the arytenoid cartilage, and one near the lower margin for the inferior cornu of the thyroid cartilage. Its—

FIG. 16.



*Outer Borders*,—give attachment to the crico-arytenoideus posticus muscle, and the longitudinal fibres of the œsophagus.

*Upper Border*,—affords attachment to the crico-thyroid membrane and the crico-arytenoidei laterales muscles.

*Lower Border*,—is connected to the upper ring of the trachea by fibrous membrane.

**Describe the Arytenoid Cartilages.** The arytenoid, or pitcher-like cartilages, are 2 in number, pyramidal-shaped, and situated on the upper margin of the cricoid cartilage posteriorly, closing in the back of the larynx. Each cartilage has 3 surfaces, 2 angles, a base and an apex. The—

*Anterior Surface*,—gives attachment to the false vocal chord, and the thyro-arytenoideus muscle.

*Anterior Angle*,—gives attachment to the true vocal chord and the thyro-arytenoideus muscle.

*Posterior Surface*,—has attached to it the arytenoideus.

*Posterior Angle*,—gives attachment to the crico-arytenoideus lateralis and posticus muscles.

*Internal Surfaces* of each look towards each other.

*Base*,—has a facet for articulation with the cricoid.

*Apex*,—articulates with the corniculum laryngis.

FIG. 17.



**What are the Cornicula Laryngis?** They are 2 small cartilaginous nodules attached to the apices of the arytenoid cartilages, and are also called the *Cartilages of Santorini*. To them are attached the aryteno-epiglottidean folds.

**What are the Cuneiform Cartilages?** The Cuneiform, or *Cartilages of Wrisberg*, are 2 rods of yellow elastic cartilage contained in the free borders of the aryteno-epiglottidean folds.

**Describe the Epiglottis.** The epiglottis is a cartilaginous lid for the larynx. It is leaf-shaped, situated behind the base of the tongue, and

attached by its *apex* to the posterior surface of the thyroid cartilage, just below the median notch. Its—

*Base*,—is free, and curves over the base of the tongue.

*Apex*,—is connected to the angle of the thyroid cartilage by the thyro-epiglottidean ligament.

*Anterior Surface*,—is attached to the hyoid bone by the hyo-epiglottic ligament, and to the tongue by 3 glosso-epiglottidean folds.

*Posterior Surface*,—covers the superior aperture of the larynx when food passes through the pharynx.

*Lateral Margins*,—are connected to the arytenoid cartilages by the aryteno-epiglottidean folds.

**Name the Ligaments of the Larynx.** They are 19 in number,—3 extrinsic ligaments, connecting the larynx to the hyoid bone; and 16 intrinsic, binding its several cartilages together, viz.—

*Extrinsic Ligaments* (3), are the—

- 1 Thyro-hyoid membrane, bounded laterally by—
- 2 Lateral thyro-hyoid ligaments.

*Intrinsic Ligaments* (16) are the—

- 1 Crico-thyroid membrane.
- 2 Crico-thyroid capsular ligaments.
- 2 Crico-arytenoid ligaments.
- 2 Crico-arytenoid capsular ligaments.
- 2 Superior thyro-arytenoid (in the false vocal chords).
- 2 Inferior thyro-arytenoid (in the true vocal chords).
- 1 Hyo-epiglottic ligament.
- 1 Thyro-epiglottic ligament.
- 3 Glosso-epiglottic folds.

**Describe the Vocal Chords.** They are in two sets, the—

*Superior or False Vocal Chords*,—containing the superior thyro-arytenoid ligaments,—extend from the angle of the thyroid cartilage around to the anterior surfaces of the arytenoids, and consist of two folds of mucous membrane, each having a free crescentic margin.

*Inferior or True Vocal Chords*,—containing the inferior thyro-arytenoid ligaments,—extend from the angle of the thyroid cartilage around to the anterior angles of the bases of the arytenoids, and consist of two thin layers of mucous membrane covering the ligaments named, each having the thyro-arytenoideus muscle external and parallel to it.

**What is the Glottis?** The Glottis or *Rima glottidis* is a narrow chink or interval between the inferior vocal chords, formed by the projection into

the cavity of the larynx of these chords and the thyro-arytenoidei muscles. Its greatest length is less than an inch, its greatest breadth about half an inch.

**What is the Ventricle of the Larynx?** An oval depression on each side, between the true and false vocal chords, leading up to the sacculus laryngis.

**What is the Sacculus Laryngis?** A blind pouch situated in the laryngeal wall at the level of the false vocal chord. It is of conical shape, and contains 60 or 70 small mucous glands which secrete a fluid for the lubrication of the true vocal chord. The sacculus is covered in by the aryteno-epiglottideus inferior muscle internally, and by the thyro-epiglottideus externally, both muscles compressing it to discharge its contents. The sacculus laryngis is also called the *Sinus of Morgagni*, and the lower part of the ventricle is sometimes named the *Sac of Hilton*.

**What class of Epithelium lines the Larynx?** Its mucous membrane is covered with *ciliated epithelium* below the level of the superior vocal chords, extending in front as high as the centre of the epiglottis. Over the rest of the larynx is *squamous epithelium*.

**Describe the Laryngeal Muscles.** They are 4 in number on each side and one in the median line, viz.—

*Crico-thyroid* (2),—from the front and side of the cricoid cartilage, *b*—into the lower and inner border of the thyroid. *c* Action, to tilt the thyroid cartilage forwards, thus elongating and making tense the vocal chords. *Nerve*, superior laryngeal.

*Crico-arytenoideus Posticus* (2),—from the cricoid cartilage posteriorly,—into the posterior angle of the base of the arytenoid cartilage. *Action*, to rotate the arytenoids outwards and open the glottis, while keeping the vocal cords tense. *Nerve*, recurrent laryngeal.

*Crico-arytenoideus Lateralis* (2), *d*—from the upper lateral border of the cricoid cartilage, *b*—into the posterior angle of the base of the arytenoid. *Action*, to rotate the arytenoids inwards and close the glottis. *Nerve*, recurrent laryngeal.

*Thyro-arytenoideus* (2), *e*—from the angle of the thyroid cartilage and the posterior surface of the crico-thyroid

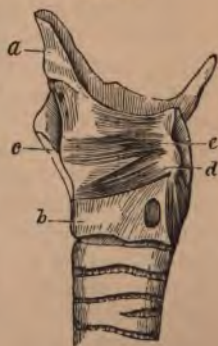

FIG. 18.

membrane,—into the base and anterior surface of the arytenoid. *Action*, to shorten and relax the vocal chords by approximating the cartilages, and to compress the sacculus laryngis. *Nerve*, recurrent laryngeal.

*Arytenoideus* (1),—from the posterior surface and outer border of one arytenoid cartilage,—into the corresponding parts of the opposite cartilage; having oblique and transverse fibres, and filling up the posterior concave surfaces of the arytenoid cartilages. *Action*, by approximating the arytenoids, to close the back part of the glottis. *Nerves*, superior and recurrent laryngeal.

A small fasciculus, called the *Kerato-cricoideus*, is sometimes found below the arytenoideus, extending from the cricoid cartilage to the inferior cornu of the thyroid.

**Describe the Muscles of the Epiglottis.** They are 3 double muscles, as follows, viz.—

*Thyro-epiglottideus* (2),—from the inner surface of the thyroid cartilage,—into the margin of the epiglottis, and the aryteno-epiglottidean fold. *Action*, to depress the epiglottis, and compress the sacculus laryngis. *Nerve*, recurrent laryngeal.

*Aryteno-epiglottideus Superior* (2),—from the apex of the arytenoid cartilage,—into the aryteno-epiglottidean fold. *Action*, to constrict the superior aperture of the larynx. *Nerve*, recurrent laryngeal.

*Aryteno-epiglottideus Inferior* (2),—from the arytenoid cartilage just above the attachment of the superior vocal chord,—into the sacculus laryngis and the margin of the epiglottis. *Action*, to compress the sacculus laryngis. *Nerve*, recurrent laryngeal.

**Name the Arteries and Veins of the Larynx.** The—

*Arteries*,—are the laryngeal branches of the superior and inferior thyroid; and the crico-thyroid branches of the superior thyroid, which anastomose on the crico-thyroid membrane with their fellows of the opposite side.

*Veins*,—empty into the superior, middle and inferior thyroid veins.

**Describe the Laryngeal Nerves.** They are the superior and recurrent laryngeal branches of the pneumogastric, joined by filaments from the spinal accessory and the sympathetic. The—

*Superior Laryngeal*,—is the nerve of sensation. It enters the larynx by a hole in the thyro-hyoid membrane, and supplies the mucous membrane, and the crico-thyroid and arytenoideus muscles. It has the following branches, namely—

External laryngeal.                      Internal laryngeal.

*Recurrent Laryngeal*,—is the motor nerve. It winds from before backwards, around the subclavian artery on the right side, around the arch of the aorta on the left side, and is distributed to all the laryngeal muscles except the crico-thyroid,—giving off, in its course, cardiac, œsophageal, tracheal and pharyngeal filaments, and finally anastomosing with the superior laryngeal nerve.

#### THE TRACHEA AND BRONCHI.

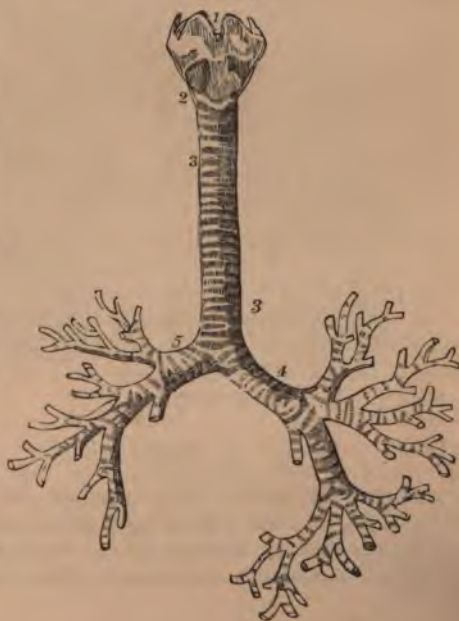
**What is the Trachea?** A membrano-cartilaginous cylindrical tube, about  $4\frac{1}{2}$  inches long, and  $\frac{3}{4}$  to 1 inch in diameter, beginning at the lower border of the larynx,<sup>2</sup> opposite the 5th cervical vertebra, and ending opposite the 3d dorsal, by its bifurcation into the two bronchi. It is composed of a fibro-elastic membrane containing 16 to 20 imperfect cartilaginous rings, connected by muscular fibres. It is lined with mucous membrane covered with ciliated columnar epithelium, and furnished with glands. Its anterior surface is convex, its posterior surface flat.

**State its chief Relations in the Neck and Thorax.**

*Anteriorly*,—it is covered from above downwards by the—

- Isthmus of the thyroid gland.
- Inferior thyroid veins.
- Sterno-hyoid muscle.
- Sterno-thyroid muscle.
- Manubrium of the sternum.
- Thymus gland.
- Arch of the aorta.
- + Innominate artery.
- Left carotid artery.
- Deep cardiac plexus.

FIG. 19.



*Posteriorly*,—it is in relation with the—

Œsophagus. Right recurrent laryngeal nerve.

*Laterally*,—with the

Common carotid arteries. Recurrent laryngeal nerves.

Thyroid gland. Pleuræ.

Inferior thyroid arteries. Pneumogastric nerves.

**Describe the Bronchi.** They are two tubes similar in formation to the trachea, extending from its bifurcation into the lungs, where they divide and subdivide into bronchial tubes, losing their rings at the 2d or 3d subdivision, whence plates of cartilage extend in their walls to their minuter ramifications. The—

*Right Bronchus*,<sup>5</sup>—is the widest, and the most horizontal, about 1 inch long, has 6 to 8 rings, and divides into 2 main divisions (its lung having 3 lobes).

*Left Bronchus*,<sup>4</sup>—is the narrowest and most oblique, nearly 2 inches long, has 9 to 12 rings, and divides into 3 main divisions (its lung having 2 lobes).

**What are the Relations of the Bronchi?** Beginning opposite the 3d dorsal vertebra, the right bronchus enters the lung opposite the 4th dorsal vertebra, the left bronchus opposite the 5th. *The Right Bronchus* lies behind the vena cava superior and the right auricle of the heart, having the right pulmonary artery at first below, then anterior to it, and the vena azygos major arching over it from behind forwards. *The Left Bronchus* passes beneath the arch of the aorta and in front of its descending portion, also in front of the œsophagus, and the thoracic duct, having the left pulmonary artery above and in front of it.

**Name the Vessels and Nerves of the Trachea and Bronchi.**

*Arteries*,—Tracheal branches of the inferior thyroid (br. of thyroid axis), and the Bronchial (brs. of thoracic aorta).

*Veins*,—open into the thyroid plexus and the bronchial veins.

*Lymphatics*,—terminate in the mediastinal glands.

*Nerves*,—are derived from the pneumogastric and its recurrent laryngeal branch, also from the sympathetic.

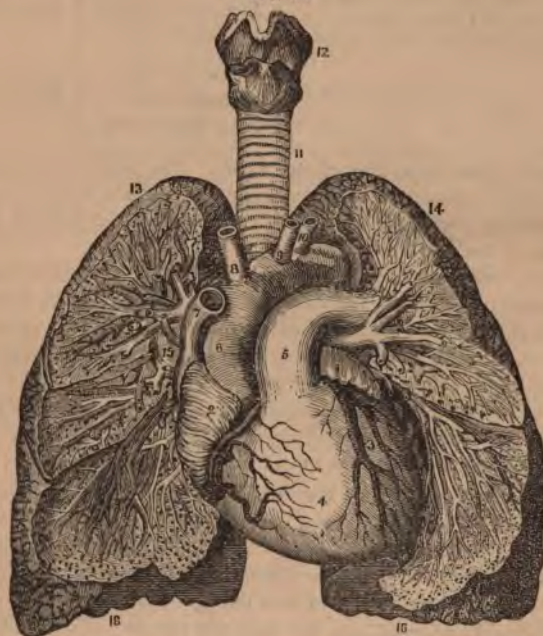
THE LUNGS.

**Describe the Lungs.** The lungs are the two essential organs of respiration, contained in the cavity of the thorax, covered by the pleuræ, and characterized by lightness (sp. gr. 0.345 to 0.746), sponginess, elasticity, and crepitation when pressed. They weigh together about 42

ounces, the right lung being the heaviest by about 2 ounces. At birth their color is a pinkish-white, mottled, as age advances, by slate-colored patches, from the deposit of carbonaceous granules in the areolar tissue of the organ. *The right lung* is the largest and has 3 lobes, *the left lung* has 2 lobes. Each lung presents for examination an—

*Apex*,<sup>13</sup>—projecting into the neck about an inch above the 1st rib, where it is in relation with the subclavian artery and the scaleni muscles.

FIG. 20.



*Base*,<sup>16</sup>—is broad, concave, and directed obliquely downwards and backwards, resting on the upper convex surface of the diaphragm.

*External Surface*,—is convex, smooth, marked by the fissures, and corresponds in form to that of the thorax.

*Inner Surface*,—is concave, excavated on the left lung for the heart, and forms part of the walls of the middle mediastinum.



*Root*,—is where the branches, vessels, and nerves enter the lung, bound together by areolar tissue. In front of the root is the phrenic nerve, behind it the pneumogastric nerve. Its chief structures are arranged in the following manner,—

From before, backwards.	{	Pulmonary veins. Pulmonary artery. <sup>5</sup> Bronchus, etc.	} V. A. B.
From above, downwards, on right side of body.	{	Bronchus, etc. Pulmonary artery. Pulmonary veins.	} B. A. V.
From above, downwards, on left side of body.	{	Pulmonary artery. Bronchus, etc. Pulmonary veins.	} A. B. V.

**Describe the Structure of the Lung.** The lung has a serous coat (the pleura); a subserous, elastic areolar tissue, investing the entire organ, and extending inwards between the lobules; and the parenchyma, or true lung-tissue; composed of—

*Lobules*,—each consists of several air-cells or compartments, arranged around the termination of a bronchiole, and surrounded by 6 plexuses of pulmonary and bronchial arteries and veins, lymphatics and nerves. Each lobule is a miniature lung, pyramidal in form, with base outwards, and about  $\frac{1}{12}$  inch in diameter.

*Alveoli, or Air-cells*,—are separated from each other by thin septa, are lined with pavement epithelium on a basement membrane, and vary in diameter from  $\frac{1}{200}$  inch to  $\frac{1}{80}$  inch.

**Name the Vessels and Nerves of the Lungs.** The lungs are nourished by the bronchial arteries, and supplied with blood for oxygenation by the pulmonary arteries.

*Bronchial Arteries*,—are derived from the thoracic aorta.

*Pulmonary Arteries*,—derived from the right heart.

*Bronchial Veins*,—open on the right side into the vena azygos, on the left side into the superior intercostal vein.

*Pulmonary Veins*,—open by 4 large orifices into the left auricle of the heart.

*Lymphatics*,—terminate in the bronchial glands.

*Nerves*,—are branches from the pneumogastric and the sympathetic, forming the anterior and posterior pulmonary plexuses, from which filaments are distributed to each lobule.

## THE PLEURÆ.

**What are the Pleuræ?** Two delicate serous sacs, one surrounding each lung and reflected over the pericardium, diaphragm and the inner surface of the thorax.

**Where do the Pleuræ meet?** For a short space behind the middle of the sternum, at the approximation of the anterior borders of the lungs.

**What Names are given to the parts of the Pleuræ?** The—  
*Pleura Pulmonalis* or *Visceral Layer*,—covers the lung, and invests that organ as far as its root.

*Pleura Costalis*, or *Parietal Layer*,—lines the inner surface of the parietes of the chest.

*Cavity of the Pleura*,—is the space between the two layers.

**What is the Ligamentum Latum Pulmonis?** The broad ligament of the lung is a triangular fold or reflection of pleura, which descends from the root of the lung posteriorly to the upper surface of the diaphragm.

**State the Differences between the Pleuræ.** The right sac is shorter, wider, and reaches higher into the neck than the left.

**Enumerate the Parts in relation with the Left Pleura.**

*Visceral Layer*,—is in contact with the left lung.

*Parietal Layer*,—is in relation with the vertebral column, the ribs, intercostal muscles and vessels, the sternum, the left sympathetic nerve, the diaphragm, the arched portion of the subelavian artery, and the origin of the left carotid, the left pneumogastric, phrenic and cardiac nerves, the trachea, œsophagus, aorta and the pericardium.

**What is the Mediastinum?** It is the space between the two pleuræ in the median line of the thorax, extending from the sternum to the vertebral column, and containing all the thoracic viscera except the lungs.

**Enumerate the contents of each of its divisions.** The—

*Anterior Mediastinum*, contains the—

Origins of the sterno-hyoid and sterno-thyroid muscles.	
Triangularis sterni muscle.	Thymus gland.
Left internal mammary vessels.	Lymphatics.

*Middle Mediastinum*, contains the—

Heart and pericardium.	Bifurcation of the trachea.
Ascending aorta.	Pulmonary arteries and veins.
Superior vena cava.	Phrenic nerves.

*Posterior Mediastinum*, contains the—

Descending aorta.	Pneumogastric nerves.
Azygos veins.	Splanchnic nerves.
Superior intercostal veins.	Thoracic duct.
œsophagus.	Lymphatic glands.

## THE URINARY ORGANS.

## THE KIDNEYS.

**Where are the Kidneys situated?** Posteriorly in the abdomen, one on each side of the spinal column, behind the peritoneum, and extending from the level of the 11th rib to near the crest of the ileum. The right kidney is lower than the left.

**What are their Dimensions?** Each one is about 4 inches by 2 by 1, and weighs from 4 to 6 oz.

**Enumerate their Relations.** The—

*Anterior Surface of the Right Kidney,*—is in relation with the right lobe of the liver, descending duodenum, and the ascending colon.

*Anterior Surface of the Left Kidney,*—with the tail of the pancreas, descending colon, and part of the spleen.

*Posterior Surface,*—with the crus of the diaphragm, 11th and 12th ribs, psoas magnus, quadratus lumborum, and the aponeurosis of the transversalis.

*Superior Extremity,*—is capped by the supra-renal capsule.

**Describe the Hilum of the Kidney.** The *Hilum* is a fissure on the inner or concave border, leading into the *Sinus* or cavity of the gland. It contains the—

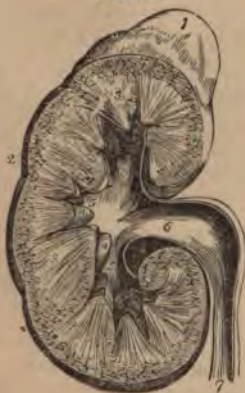*Renal Vein,*—in front.

*Renal Artery,*—next in order.

*Ureter,* or Excretory Duct,—behind and below.

**Describe the Kidney-structure.** A vertical section presents the—

FIG. 21.



*Pelvis or Sinus,*<sup>6</sup>—the cavity, forming the beginning of the ureter<sup>7</sup> or excretory duct of the gland. Its divisions are the *Infundibula*<sup>5</sup> (3), and these are again divided into *Calices*<sup>4</sup> or pouches, into which open the orifices of the pyramids, 1000 orifices situated on each *Papilla*. [See page 45.]

*Medullary Substance,*<sup>3</sup>—consists chiefly of the tubes of Bellini and Henle, arranged in *Pyramids of Malpighi*, whose apices project into the calices of the pelvis.

*Cortical Substance,*<sup>2</sup>—forms the surface of the gland, and consists of uriniferous tubules (straight and convoluted), Mal-

pighian bodies, blood-vessels, nerves, lymphatics, connective tissue, and a granular matrix. It is of a red color, and is prolonged down to the pelvis between the pyramids, these prolongations being named the *Columns of Bertin*.

**Describe the Tubuli Uriniferi.** The uriniferous tubes begin at the Malpighian corpuscles in the Capsules of Müller, and end at the orifices on the surfaces of the papillæ. Their various portions are the—

*Convolved Tubes of Ferrein*,—in the cortical substance.

*Looped Tubes of Henle*,—descending from the former and ascending into the next mentioned.

*Straight Tubes of Bellini*,—in the medullary substance, arranged in pyramids, the *Pyramids of Malpighi*.

**What are the Pyramids of Ferrein?** They are pyramidal arrangements of the tubes of Ferrein at the bases of the pyramids of Malpighi.

**What are the Malpighian Bodies?** They are small red bodies found in the cortical substance, each formed by the dilated extremity of a tube of Ferrein, about the  $\frac{1}{16}$  inch in diameter, and consisting of the—

*Malpighian Tuft*,—a tuft of capillary vessels, the termination of some branches of the renal artery and vein.

*Capsule of Müller*,—the dilated extremity of a tube of Ferrein, investing the Malpighian tuft probably by two layers, similarly to the pleural investment of the lungs.

**How is the Kidney invested?** By a dense fibrous capsule, which is continued inwards at the hilum, to line the sides of the sinus and form sheaths around the vessels. The kidney is also surrounded by a large quantity of fat.

**Enumerate the various divisions of the renal Vessels.** They are all derived from the renal artery and the renal vein, but in their course have received different names, as follows, viz.—

*Renal Artery*,—branch of the aorta. Divides into the—

*Primary Branches*, 4 or 5,—arising just external to the hilum, again subdivide and enter along the columns of Bertin.

*Arterial Arches*,—over the bases of the pyramids.

*Ascending and Descending Branches*,—which supply the cortical and medullary substances with nutrition.

*Afferent Vessels*,—to the Malpighian bodies.

*Malpighian Tufts*,—within the Malpighian bodies.

*Efferent Vessels*,—whether arterial or venous, is undecided.

*Venous Plexuses*,—on the convolved uriniferous tubes.

*Stars of Verheyen*,—are venous plexuses of stellate form, situated on the surface of the kidney.

*Ascending and Descending Veins*,—to the cortical and the medullary substances respectively.

*Venous Arches*,—over the bases of the pyramids.

*Primary Veins*,—end in the renal vein.

*Renal Vein*,—empties into the inferior vena cava.

**Whence are the Nerves of the Kidney derived?** From the renal plexus, which is formed by filaments from the solar plexus and the lesser splanchnic nerve.

### THE URETERS.

**What is the Ureter?** The excretory duct of the kidney, forming, by its upper expanded portion, the cavity of that gland. It is a musculo-membranous tube, 16 to 18 inches long, as large as a small goose-quill; and ends at the base of the bladder, into which it opens obliquely by a constricted orifice, about 2 inches from the orifice of its fellow. The ureter commences in the—

*Calices*,—7 to 13 small tubes, embracing the papillæ of the kidney, and joining to form the—

*Infundibula*,—3 or 4 in number, which unite in the—

*Pelvis*,—a funnel-shaped dilatation of the upper portion of the ureter.

**Describe its course.** It descends obliquely inwards along the posterior wall of the abdomen, enters the posterior false ligament of the bladder in the male, and that of the uterus in the female, through which it passes forwards and inwards to the posterior angle of the trigone vesicæ, lying between the muscular and mucous coats of the bladder, for about three-fourths of an inch.

**What are its Relations?** It lies upon the psoas muscle, behind the peritoneum and below the spermatic vessels, over the common iliac or the external iliac artery, behind the ileum on the right side, behind the sigmoid flexure on the left. The right ureter lies close to the outer side of the inferior vena cava.

**What is its Structure?** The ureter has 3 coats, a fibrous, a muscular, and a mucous; the epithelium of the mucous coat is different from that of the urethra, the bladder, or the uriniferous tubes, being spheroidal in shape.

## THE BLADDER.

**What is the Bladder?** It is the urinary reservoir, a musculo-membranous sac, situated in the anterior portion of the pelvis, behind the pubes. When moderately distended it measures about 5 by 3 inches, and holds about a pint. Its—

*Summit*,—is connected to the umbilicus by the *Urachus* and the obliterated hypogastric arteries of the foetus, forming three fibrous cords, the superior ligament of the bladder.

*Body*,—is in relation in front with the triangular ligament, the symphysis pubis, and the internal obturator muscles,—behind it is covered by peritoneum, and is in relation with the rectum in the male, in the female with the uterus and upper part of the vagina. Each side is crossed obliquely by the obliterated hypogastric artery and the vas deferens, the first passing from below forward, the latter from below backward.

*Fundus or Base*,—rests on the second portion of the rectum in the male, on the lower part of the cervix uteri and adherent to the anterior wall of the vagina in the female. It is partly covered by peritoneum.

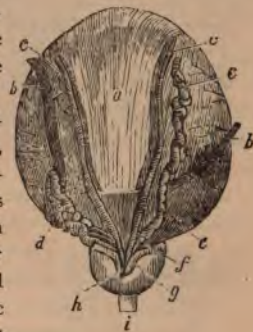*Cervix or Neck*,—is constricted and continuous with the urethra.<sup>i</sup> It is surrounded in the male by the prostate gland,<sup>h</sup> and is directed downward and forward.

**Name the Ligaments of the Bladder.** They number 10, of which 5 are true ligaments and 5 are false, being folds of peritoneum. They are as follows,—

<i>True Ligaments.</i>	<i>False Ligaments.</i>
2 Anterior (pubo-prostatic).	2 Posterior.
2 Lateral.	2 Lateral.
Superior (the Urachus, etc.).	Superior.

**What is the Urachus?** It is the obliterated remains of a canal, which in the embryo connects the bladder with the allantois. It is situated between the two obliterated hypogastric arteries, and with them forms the superior ligament of the bladder, connecting the summit of that organ with the umbilicus.

FIG. 22.



*Bulb of the Urethra*,<sup>18</sup>—is the upper end of the spongy portion, projects backwards for  $\frac{1}{4}$  inch, and contains the orifices of Cowper's glands.

*Fossa Navicularis*,—is the lower dilatation of the urethra, and is situated within the glans penis.

*Lacuna Magna*,—the largest of several orifices of mucous follicles, situated on the roof of the fossa navicularis.

*Glands of Littre*,—are numerous mucous glands and follicles, opening into the urethral canal, their orifices being directed forwards.

**What is the Structure of the Urethra?** It has 3 coats, a mucous, a muscular, and an erectile. The—

*Mucous Coat*,—is continuous with that of the whole urinary tract and the ducts of the glands opening therein. Its epithelium is columnar, except in the fossa navicularis, where it is squamous.

*Muscular Coat*,—consists of a layer of longitudinal fibres of the unstriped variety. [For the voluntary muscles of the urethra see the Compressor urethrae and Accelerator urinae, ANATOMY, page 84.]

*Erectile Coat*,—is the corpus spongiosum of the penis, and a thin layer continued therefrom around the membranous and prostatic portions.

#### THE FEMALE URETHRA.

**Enumerate the Characteristics of the Female Urethra.** It is about  $1\frac{1}{2}$  inch long, imbedded in the anterior wall of the vagina, perforating the triangular ligament, and surrounded by the fibres of a compressor urethrae muscle. Its diameter is about  $\frac{1}{4}$  inch, but is capable of considerable dilatation, being surrounded by softer structures than those around the male urethra.

### THE MALE GENERATIVE ORGANS.

#### THE PROSTATE GLAND.

**Where is the Prostate Gland?** It encircles the neck of the male bladder, its apex touching the deep perineal fascia, its under surface resting on the rectum. It is perforated by the urethra and the common seminal ducts, and its ducts open into the prostatic portion of the urethra.

**State its Dimensions and Characteristics.** It measures about  $1\frac{1}{2}$  inch by 1 inch by  $\frac{3}{4}$  inch, weighs about  $\frac{3}{4}$  oz., resembles a horse-chestnut in size and shape, and consists of three lobes, two being lateral and of equal size, the third or middle lobe being a small prominence situated in the notch between the lateral lobes.

**What is its Structure?** The prostate gland is composed of glandular substance and muscular tissue, inclosed in a fibrous capsule.

**How is it Held in position?** By the pubo-prostatic ligaments of the bladder, the posterior layer of the deep perineal fascia, and by the anterior portion of the levator ani muscle.

#### COWPER'S GLANDS.

**Where are Cowper's Glands?** They are situated between the two layers of the deep perineal fascia, one on each side of the membranous portion of the urethra, close behind the bulb, and inclosed by the transverse fibres of the compressor urethrae muscle.

**Where do their Ducts open?** On the floor of the bulbous portion of the urethra, after traversing the wall of the urethra for about one inch, between its mucous and muscular coats.

#### THE PENIS.

**Of what is the Penis Composed?** Of a mass of erectile tissue arranged in three compartments of cylindrical shape, each surrounded by a fibrous sheath which is prolonged inwards, forming numerous bands (trabeculae), and dividing the compartment into a number of spaces. The compartments are named the 2 corpora cavernosa and the corpus spongiosum.

**Describe the Corpora Cavernosa.** (19, Fig. 23) They lie side by side, forming the upper and lateral parts of the penis, are joined together along their anterior three-fourths, their posterior one-fourth forming the *crura*, which arise from the tuberosities of the ischia and their descending rami, meet beneath the symphysis pubis, forming two grooves, one above for the dorsal vessels and nerves, the inferior one for the corpus spongiosum. The—

*Bulb of the Corpus Cavernosum*,—is a slight enlargement on each crus, near its junction with its fellow.

*Suspensory Ligament*,—connects the root of the organ to the symphysis pubis.

*Septum Pectiniforme*,—is a portion of the fibrous septum between the corpora cavernosa. This septum extends but two-thirds along the penis, and is wanting for its anterior third.

**Describe the Corpus Spongiosum.** It is an erectile tube, lying in the inferior groove between the two corpora cavernosa, having within it

G. M. Moore January - 1885 -



the urethra, and being expanded at both ends to form the glans penis and the bulb. It is composed of trabecular structure derived from a fibrous sheath, and containing erectile tissue. The—

*Bulb of the Corpus Spongiosum*,—receives the urethra and is surrounded by the accelerator urinæ muscle.

*Glans Penis*,—is the external expansion of the corpus spongiosum, and covers by its base the ends of the two corpora cavernosa. Its base presents a rounded border, called the *corona glandis*, behind which is a deep sulcus, the *cervix*.

*Meatus Urinarius*,—the external orifice of the urethra, is situated at the summit of the glans penis.

*Prepuce*,—a prolongation of the integument of the penis, covering or partly covering the glans penis.

*Frenum Preputii*,—a fold of mucous membrane lying along the raphe of the glans penis, and connecting the prepuce thereto.

*Glands of Tyson*,—small lenticular sebaceous glands opening on the corona and cervix of the glans, and secreting an odorous sebaceous matter.

**Of what does Erectile Tissue consist?** Of an intricate venous plexus, supplied by afferent arteries and emptied by efferent veins. Such are the essential features of the erectile tissue of the penis, which is lodged in the interspaces between the trabeculæ of the fibrous structure.

**What are the Helicine Arteries?** They are peculiar vine-like arterial branches which project in a convoluted manner into the venous plexuses in the posterior portion of the penis.

**Enumerate the Vessels and Nerves of the Penis?** Its—

*Arteries*,—are derived from the internal pudic, and are the—

Artery of the bulb, to the corpus spongiosum.

Artery of the corpus cavernosum, to that structure.

Dorsal artery of the penis, to the glans, prepuce, and skin.

*Veins*,—empty into the dorsal vein of the penis, the prostatic plexus and the pudic vein. The venous plexuses of the erectile tissue are very intricate, and remarkably developed.

*Lymphatics*,—the superficial terminate in the inguinal glands; the deep set joins the deep lymphatics of the pelvis.

*Nerves*,—are derived from the internal pudic nerve, and the hypogastric plexus.

## THE TESTES AND THEIR APPENDAGES.

**What are the Testes?** The glandular organs which secrete the seminal fluid. They are two oval bodies suspended obliquely in the scrotum by the spermatic cords, each measuring about an inch in diameter, and weighing  $\frac{3}{4}$  oz. to an ounce.

**What is the Scrotum?** A cutaneous pouch, consisting of 2 layers, the integument and the *dartos*, the latter being a contractile vascular tunic, continuous with the superficial fascia of the thighs and perineum, and forming a septum in the scrotum between the two cavities for the testes.

**What are the Essential Coats of the Testicle?** They are 3 in number, as follows,—

*Tunica Vaginalis*,—the serous covering, having a visceral layer (*tunica vaginalis propria*) and a parietal layer (*tunica vaginalis reflexa*). It was originally derived from the peritoneum, and the upper part being obliterated, it remained a closed sac.

*Tunica Albuginea*,<sup>1</sup>—the fibrous covering formed of white fibrous tissue, and forming an incomplete vertical septum within the gland, the *Corpus Highmorianum*<sup>2</sup> or *Mediastinum testis*, from which fibrous bands or trabeculae cross the gland, dividing its interior into spaces for the lobules of the organ.

*Tunica Vasculosa*,—the pia mater testis, is the vascular tunic, lying beneath the tunica albuginea, and giving off numerous processes between the lobules.

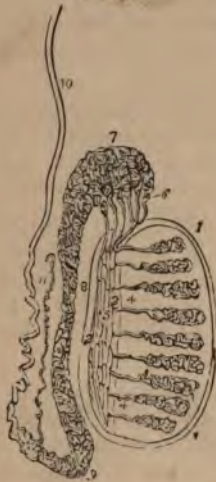**Name the Coverings of the Testicle.** From without inwards they are 6 in number, as follows,—

1. *Skin*,—of the scrotum, closely adherent to the *dartos*.
2. *Dartos*,—or superficial fascia.
3. *External Spermatic Fascia*,—intercolumnar fascia, derived from the margins of the external abdominal ring.
4. *Cremasteric Fascia*,—derived from the lower border of the internal oblique muscle.
5. *Internal Spermatic Fascia*, or *Fascia Propria*,—the infundibuliform process of the transversalis fascia.
6. *Tunica Vaginalis*,—originally a process of peritoneum.

**Describe the Structure of the Testicle.** The glandular structure is composed of small convoluted tubes, the *tubuli seminiferi*,<sup>3</sup> which are collected into *lobules*, about 300 in number; from which straight ducts, the *vasa recta*,<sup>4</sup> enter the mediastinum and form an ascending plexus of *vasa-*

tomosing tubes, the *rete testis*,<sup>5</sup> which gives off some 12 to 20 ducts, the

FIG. 24.



*vasa efferentia*;<sup>6</sup> these perforate the tunica albuginea of the testis, and form a number of conical masses, the *coni vasculosi*,<sup>7</sup> which together constitute the *globus major*<sup>7</sup> of the epididymis.<sup>8</sup>

**What is the Epididymis?**<sup>8</sup> It is an appendix to the testicle, lying along its posterior border, and consists of a single duct about 20 feet in length when unraveled, but which is wound upon itself to occupy a very small space. The—

*Globus Major*,<sup>7</sup>—is formed by the *coni vasculosi*, or efferent ducts of the testis, which therein open into the single duct which forms the epididymis.

*Body*,—is formed by the convolutions of the tube, held together by fine connective tissue.

*Globus Minor*,<sup>9</sup>—the lower expanded portion, similarly formed, and connected to

the testis by fibrous tissue.

*Vasculum Aberrans*,<sup>11</sup>—a narrow tube, sometimes found opening into the canal of the epididymis near its lower end, and ending in a blind extremity.

**Describe the Vas Deferens.**<sup>10</sup> It is the continuation of the epididymis, and is the excretory duct of the testicle. Beginning at the *globus minor* it ascends along the back of the spermatic cord to the external abdominal ring, where it enters the inguinal canal, and penetrates the abdominal cavity through the internal abdominal ring. Descending into the pelvis it passes between the bladder and the rectum, along the inner side of the *vesicula seminalis*, and at the base of the prostate gland it joins with the duct of the *vesicula seminalis* to form the ejaculatory duct. The *vas deferens* is about 2 feet long, and has a canal of only half a line in diameter. Its walls are very dense, making it feel like a piece of wire or whipcord when grasped between the fingers.

**Name the Arteries of the Testicle.** The *Spermatic Artery* supplies the gland itself; but the coverings of the testicle are supplied by the—

*Superficial External Pudic*, } —branches of the Femoral.  
*Deep External Pudic*, }

*Superficial Perineal*,—branch of the Internal Pudic, from the Internal Iliac.

*Cremasteric*,—branch of the Epigastric, from the External Iliac.

**Name the Nerves of the Testicle.** They are the—

*Ilio-inguinal*, } —branches of the Lumbar Plexus.  
*Ilio-hypogastric*, }

*Superficial Perineal*,—branch of the Internal Pudic nerve.

*Inferior Pudendal*,—branch of the Small Sciatic nerve.

*Genital*,—branch of the Genito-crural nerve.

**Describe the Spermatic Cord.** It extends from the internal abdominal ring to the globus minor of the epididymis, and is about 4 inches long. It consists of the following-named 10 structures, bound together by areolar tissue and invested by its coverings. These structures are the—

Vas Deferens.	Spermatic Plexus of Nerves.
Spermatic Artery.	Branch of the Ilio-inguinal Nerve.
Cremasteric Artery.	Branch of the Genito-crural Nerve.
Artery of the Vas Deferens.	Vasculum Aberrans.
Spermatic Veins.	Lymphatics.

**What is the Pampiniform Plexus?** A venous plexus formed by the spermatic veins and branches from the epididymis. It forms the chief mass of the spermatic cord, and unites into a single trunk, which on the right side empties into the inferior vena cava, on the left side into the left renal vein.

**Describe the Vesiculæ Seminales.** They are two sacculated membranous pouches, serving as reservoirs for the semen, and are filled by the backing up of that fluid from the vasa deferentia. They are about  $2\frac{1}{2}$  inches in length, and are situated between the base of the bladder and the rectum. The—

*Ejaculatory Ducts*,—one on each side, are formed by the junction of the vasa deferentia with the ducts of the vesiculæ seminales. They are about  $\frac{3}{4}$  inch in length, and terminate in the prostatic portion of the urethra, by orifices opening on the sides of the veru montanum.

**Describe the Descent of the Testes.** In early foetal life the testes are situated in the abdominal cavity, just below and in front of the kidneys, and are each connected to the dartos of the scrotum and the tissues about the inguinal canal by the 3 processes of a cord named the *gubernaculum testis*, which is supposed to gradually shorten itself and draw the testis down. At the beginning of the 5th month the descent begins; during the 7th month the testicle enters the inguinal canal, and ordinarily arrives in

the scrotum by the end of the 8th month. A process of peritoneum is supposed to be carried down in front of the testis; which process, by obliteration of the canal, becomes a separate structure, the *tunica vaginalis*. The structures of the inguinal canal are also supposed to be brought down with the testicle, and to constitute some of its coverings. [See *ante*, page 53.]

## THE FEMALE ORGANS OF GENERATION.

### THE VULVA.

**Enumerate the Organs comprised in the Vulva.** They are the *mons veneris*, the *labia majora*, *labia minora*, *clitoris*, *meatus urinarius*, and the orifice of the vagina.

**Describe the Labia Majora.** They are two prominent folds formed of skin, mucous membrane, areolar and dartoid tissues;—are joined together at the *mons veneris*, forming the *anterior commissure*, and also in front of the perineum, where they form the *posterior commissure*.

**What are the Labia Minora?** The *labia minora* or *Nymphæ* are two folds of mucous membrane, lost posteriorly in the *labia majora*, but anteriorly they embrace the *clitoris*, forming the *prepuce* of that organ.

**Describe the other parts comprised in the Vulva.** The—

*Mons Veneris*,—is the eminence in front of the pubes. It is formed of adipose tissue, and at puberty becomes covered with hair.

*Clitoris*,—is situated beneath the anterior commissure, its *glans* only appearing as a small rounded tubercle between the anterior extremities of the *labia minora*. It is a diminutive penis in all but the urethra, having a body, *crura*, *glans*, *prepuce*, suspensory ligament and muscles, the *erectores clitoridis*.

*Bulbi Vestibuli*,—are two oblong masses extending from the *clitoris* along the sides of the vestibule, and consisting of a venous plexus surrounded by a fibrous membrane.

*Pars Intermedia*,—is a small venous plexus situated between the *glans clitoridis* and the *bulbi vestibuli*.

*Vestibule*,—is a triangular depression in front of the vaginal orifice, bounded laterally by the *labia minora*.

*Meatus Urinarius*,—situated in the vestibule, about an inch below the *clitoris*, and close to the vaginal orifice.

*Orifice of the Vagina*,—is surrounded by the sphincter vaginae muscle, and in the virgin is sometimes partly closed by the hymen.

*Hymen*,—a fold of mucous membrane situated across the lower part of the vaginal orifice, of various shapes, but usually semilunar, the concavity upwards. It is frequently absent in virgins, and after sexual intercourse its rupture and cicatrization give rise to small eminences along the margin of the vaginal orifice, named the *caruncule myrtiformes*.

*Fourchette*,—a small transverse fold just behind the posterior margin of the vaginal orifice.

*Fossa Navicularis*,—the space between the fourchette and the posterior commissure of the vulva.

*Glands of Bartholine*,—one on each side of the vaginal orifice, their ducts opening on the inner sides of the labia minora. They are the analogues of Cowper's glands in the male.

#### THE VAGINA.

**Describe the Vagina.** It is a curved canal extending from the vulva to the uterus, placed between the bladder and the rectum. Its length is about 4 inches along its anterior wall, an inch longer posteriorly, and its walls are usually in contact with each other. It is very dilatable, especially at its upper part.

**What is its Structure?** It consists of a muscular coat externally, a layer of erectile tissue, and a mucous lining covered with squamous epithelium, and furnished with mucous glands and follicles. The—

*Columns of the Vagina*,—are two longitudinal raphés, situated along its mucous surface, connected by numerous transverse ridges, or *rugæ*.

**What are the Relations of the Vagina?** They are—

*Anteriorly*,—the urethra and the base of the bladder.

*Posteriorly*,—the anterior wall of the rectum, and the recto-uterine fold of peritoneum, which forms *Douglas' cul-de-sac* behind its upper fourth.

*Laterally*,—are attached the broad ligaments of the uterus, the levatores ani muscles, and the recto-vesical fascia.

*Superiorly*,—it is attached to the cervix uteri above the os, and higher on the posterior wall than anteriorly.

#### THE UTERUS AND ITS APPENDAGES.

**Where is the Uterus situated?** In the pelvic cavity, between the bladder and the rectum and above the vagina.

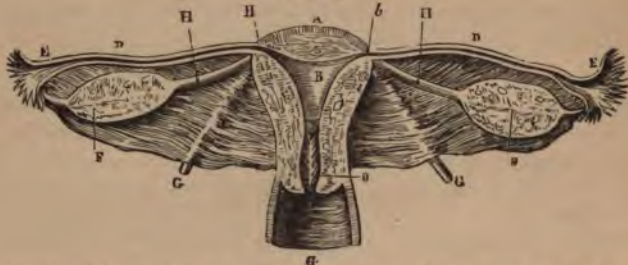**Describe the Uterus.** It is a hollow, pear-shaped, muscular organ, measuring about 3 inches long, 2 inches broad, and 1 inch thick, flattened from before backward, placed base upward, and forming an angle with the vagina, which partially receives its cervix. The—

*Fundus* *A*—is broad, convex, having walls  $\frac{5}{8}$  inch thick, and is covered by peritoneum.

*Body*,—is about  $1\frac{5}{8}$  inch long, walls  $\frac{1}{2}$  inch thick, flat anteriorly, convex posteriorly, concave laterally, and joined to the bladder by its lower anterior fourth. It is invested by peritoneum posteriorly, and in front for its upper three-fourths.

*Cervix, or Neck*,—is the lower constricted portion, about  $1\frac{3}{8}$  inch long, walls  $\frac{1}{4}$  inch in thickness, and is embraced for  $\frac{1}{2}$  to  $\frac{3}{4}$  inch by the upper extremity of the vagina.

FIG. 25.



*Cavity of the Body*, *B*—is small and triangular, flattened from before backwards, about  $1\frac{1}{8}$  inch in length, and has two lateral *cornua* above, and a constricted orifice—the *os internum uteri*—at its lower angle, opening into the cavity of the cervix.

*Cavity of the Cervix*,—is spindle-shaped, about  $1\frac{3}{8}$  inch long, and presents on its inner surface transverse folds of mucous membrane proceeding from a longitudinal fold, giving an appearance named the *arbor vite*.

*Os Uteri or Os Tinæ*,—is a transverse orifice at the lower end of the cervical cavity, opening into the vagina, and having an anterior and a posterior lip.

**Enumerate the Ligaments of the Uterus.** The proper ligaments of the uterus are 6 in number, 2 anterior, or *utero-vesico pubic*, 2 posterior, or *utero-recto-sacral*, and 2 lateral, or *broad ligaments*, all composed of peritoneum. The—

*Broad Ligaments*,—pass from the sides of the uterus to the lateral walls of the pelvis, and form a septum across the pelvic cavity. They contain, between the two folds of peritoneum of which they are composed, the Fallopian tubes, the ovaries, and the so-called round ligaments.

**What are the Round Ligaments<sup>G</sup> of the Uterus?** They are two cords, composed of areolar and fibrous tissue, muscular fibres, vessels and nerves, extending one on each side, from the lateral aspects of the fundus uteri, through the inguinal canals, to the labia majora, where they are lost. Each ligament lies, for a part of its course, between the two layers of the broad ligament, and is covered by a process of peritoneum.

*Canal of Nuck*,—is the extension of the above-named process of peritoneum into the inguinal canal. It exists in the fetus, and is usually obliterated in the adult.

**Describe the Uterine Structure.** The uterus has 3 coats, peritoneal, muscular and mucous. Its—

*Serous or Peritoneal Coat*,—invests the body of the organ, excepting on its lower anterior fourth.

*Muscular Coat*,—constitutes the chief bulk of the uterus. It consists of bundles of unstriped muscular fibres, disposed in 3 layers interlaced together; circular fibres predominating in the cervix, longitudinal fibres in the body.

*Mucous Coat*,—is very thick,  $\frac{1}{2}$  to  $\frac{1}{3}$  inch, and closely adherent to the muscular tissue, having no basement layer of connective tissue. It is covered with ciliated columnar epithelium, and studded with mucous follicles and glands, which are most numerous in the cervix. The latter, when distended by their own secretions, form sacs, which Naboth mistook for human ova, and hence were named the *Ovules of Naboth*.

**Enumerate the Uterine Vessels and Nerves.** Its—

*Arteries*,—are the Uterine, from the anterior trunk of the external iliac, anastomosing with twigs from the Ovarian,—(spermatic branch of the abdominal aorta.)

*Veins*,—accompany the arteries, and in the impregnated state become sinuses. They end in the uterine plexuses.

*Lymphatics*,—those of the cervix end in the sacral and internal iliac glands; those of the fundus in the lumbar glands.

*Nerves*,—are derived from the inferior hypogastric and ovarian plexuses, and from the 3d and 4th sacral nerves.

**Describe the Fallopian Tubes or Oviducts.** They are two tubes, each about 5 inches in length, and  $\frac{1}{8}$  inch in calibre, situated in the free margin of the broad ligament, and extending from the superior angles of the uterus<sup>b</sup> outwards, to terminate in free, trumpet-shaped ends, the *fimbriated extremities*,<sup>E</sup> surrounded by fringe-like processes, the *fimbriae*, &c.



which one or more are attached to the ovary of that side. Their structure is similar to that of the uterus, their mucous lining being continuous with the uterine mucous membrane and with the peritoneum. The tubes open at one end into the uterus at its cornua, at the other end into the peritoneal cavity.

**What are the Ovaries?** Two oval bodies,<sup>F</sup> of whitish color, situated in the broad ligament, one on each side of the uterus, to which they are attached by the *ligaments of the ovaries*,<sup>H</sup> and behind and below the Fallopian tubes. They each measure about  $1\frac{1}{2}$  inch by  $\frac{3}{4}$  by  $\frac{1}{3}$ , and are invested by peritoneum, except posteriorly.

**What is the Structure of the Ovaries?** They are composed of a vascular stroma containing the *Graafian Vesicles or Ovisacs*, in various stages of development, and are surrounded by a dense fibrous coat, the *Tunica Albuginea*.

**Describe the Graafian Vesicles.** They are the ovisacs containing the human ova, are very numerous (about 70,000 in each ovary), vary in diameter from  $\frac{1}{80}$  to  $\frac{1}{50}$  inch, but after puberty a few are found of from  $\frac{1}{20}$  to  $\frac{1}{8}$  inch or more. Each vesicle presents an—

*External Coat*,—of fibro-vascular structure.

*Ovi-capsule*,—or internal coat.

*Membrana Granulosa*,—a layer of nucleated cells, which at one point are heaped up around the ovum in a mature vesicle, forming the *discus proligerus*.

*Fluid*,—of transparent, albuminous character, containing the ovum in immature vesicles.

**What is the Ovum?** It is a spherical mass of protoplasm, about  $1\frac{1}{20}$  inch in diameter when fully developed. It presents a—

*Vitelline Membrane*,—also called the *Zona Pellucida*,—a colorless envelope, in which is contained the—

*Vitellus or Yolk*,—composed of granules in a fluid substance, one of which is called the—

*Germinal Vesicle*,—which contains a smaller body named the *germinal spot*, measuring about the  $\frac{1}{30000}$  of an inch in diameter.

**What is the Corpus Luteum?** It is a puckered yellow spot in the substance of the ovary, produced as a result of the rupture of a Graafian vesicle and the discharge of an ovum, probably by the fatty degeneration of the extravasated blood. The—

*True Corpus Luteum*,—is that of pregnancy, and may increase in size, not disappearing until full term.

*False Corpus Luteum*,—occurs when impregnation has not taken place, and is absorbed in about 3 months.

**What is the Pampiniform Plexus?** A venous plexus near the ovary, formed by the veins of that organ.

**Enumerate the Arteries and Nerves of the Ovaries.** Their—*Arteries*,—are the Ovarian (or spermatic), from the aorta, which also supply the Fallopian tubes, anastomosing with the uterine arteries. *Nerves*,—are derived from the Spermatic plexus.

**What is the Parovarium?** The Parovarium, or *Organ of Rosenmüller*, is a group of tubules, situated in the broad ligament, between the ovary and the Fallopian tube, and converging to a large duct, the *Duct of Gartner*, which ramifies in the broad ligament, and descends along the side of the uterus. It is thought to be a remnant of the Wolffian body of foetal life.

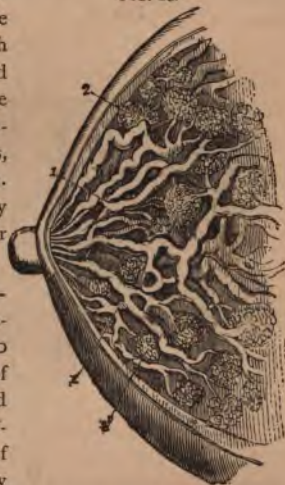#### THE MAMMÆ.

**Describe the Mammæ.** The breasts are two hemispherical eminences, situated one on each latero-anterior aspect of the chest, extending from the sternum to the axilla, and from the 3d rib to the 7th. Each breast contains the *Mammary Gland* and is surmounted by the *Nipple*, around the base of which is a zone of colored cutaneous tissue, the *Areola*, pink in virgins, darker in women who have borne children. In the male the mammæ are rudimentary organs, but capable of development under special circumstances.

**What is the Structure of the Mammary Gland?** It is a compound conglomerate gland, composed of 15 or 20 lobes and their ducts,<sup>1</sup> with a packing of areolar and adipose tissue, and enveloped by a fibrous capsule which forms septa between the lobes. Each lobe is made up of lobules,<sup>2</sup> and these again are formed by the aggregation of the *acini* or terminal vesicles, in which the milk is secreted. The—

*Tubuli Lactiferi* or *Tubuli Galactophori*,<sup>1</sup>—are the excretory ducts of the lobes, one for each. They are formed by the junction of the

FIG. 26.



ducts from each lobule, and converge towards the areola, beneath which they form *Ampullæ* or dilatations, and thence, piercing the nipple, open on its summit by separate orifices.

**What is the Circulus Venosus?** An anastomotic venous circle around the base of the nipple, from which larger veins run outwards and terminate in the axillary and internal mammary veins.

**Name the Arteries of the Mammæ?** They are derived from the thoracic branches of the axillary, the intercostals, and the internal mammary arteries.

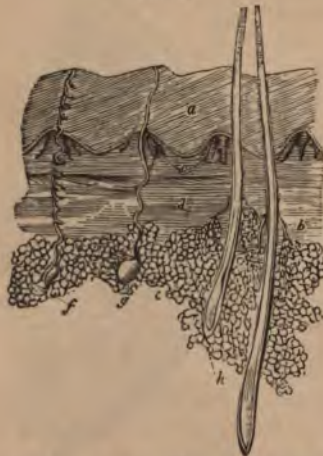### THE ORGANS OF SENSE.

#### THE SKIN AND ITS APPENDAGES.

**Name the Divisions of the Skin.** They are the—

<i>Epidermis or Cuticle,</i> <sup>a</sup>	{	Superficial Layers of Epithelium.
		Rete Mucosum, or Pigmentary Layer.
<i>Derma, or True Skin,</i>	{	Papillary Layer. <sup>c</sup>
		Corium. <sup>d</sup>

FIG. 27.



**What Structures lie in and beneath the Skin?**

*In the Derma* are the—

Sensitive papillæ,<sup>c</sup> containing the Tactile corpuscles.

*In the Subcutaneous Cellular Tissue* are the—

Sweat-glands.<sup>f, s</sup>

Sebaceous glands.<sup>i</sup>

Hair-roots.<sup>h</sup>

Fat cells.<sup>e</sup>

*Perforating* both the Derma and the Epidermis are the—

Ducts of the sweat-glands.

Hair-follicles,—into which most of the sebaceous ducts open.

Ducts of the sebaceous glands, occasionally.

**What is the Structure of the Epidermis?** It is an unorganized epithelial structure, having no vessels or nerves. The cells of which it is composed are developed in the liquor sanguinis which is exuded on the upper surface of the derma. They are flat and dry on the surface, round

and softer in the central portion, columnar and softest in the deepest layer.

*Rete Mucosum*,—is the lowest portion of the epidermis. It contains pigment cells, giving color to the skin.

**Describe the Structure of the Derma.** The true skin is a highly organized, tough yet elastic tissue, and serves to protect the parts beneath, to perform the functions of excretion and absorption, and as the chief seat of the sense of touch. It consists of fibro-areolar tissue, vessels and nerves.

The—

*Papillary Layer*,—situated next to the rete mucosum, is covered with minute conical elevations (papillæ),  $\frac{1}{100}$  inch high  $\frac{1}{25}$  inch in diameter at their base, very numerous and arranged in parallel curved lines wherever sensibility is greatest. Each papilla contains a capillary loop or plexus, the termination of one or more sensory nerves,—and in highly sensitive parts, an oval-shaped body, the *tactile corpuscles*.

*Corium*,—the lower layer of the derma, is composed chiefly of interlacing bundles of white fibrous tissue, in which are mingled some yellow elastic fibres, also plain muscular fibres wherever hairs are found,—and lymphatic vessels, blood-vessels and nerves, in plexiform arrangement.

**Describe the Nails.** They are flat, horny structures, a modification of the epidermis, molded upon the derma at the dorsal surface of the terminal phalanges of both fingers and toes. Each nail is convex on its outward surface, and is imbedded by its *root* into a fold of the skin. Its—

*Matrix*,—is that portion of the derma directly beneath the nail. It is covered with highly vascular papillæ. The—

*Lunula*,—is a white crescentic portion of the nail nearest to its root, produced by the diminution in number and size of the papillæ beneath.

**What are the Hairs?** They are also a modified form of the epidermis, found over nearly the whole surface of the body, much varied in size and color. Each hair consists of a—

*Root*,—is lodged in an involution of the epidermis called the *hair-follicle*, which sometimes extends into the subcutaneous cellular tissue. The root rests on a vascular papilla at the bottom or *bulb* of the follicle, which supplies it with the material for its growth.

*Shaft*,—is the projecting portion of the hair. It consists of a medulla in the centre, next a fibrous portion, externally a cortex of thin, flat scales. The finest hairs have no medulla.

*Point*,—consists of the fibrous portion and the cortex, the medulla being wanting.

**Where are the Sebaceous Glands most abundant?** In the scalp, the face, around the anus, and the apertures of the nose, mouth and external ear. The largest are the—

*Meibomian Glands*,—situated in the eyelids (see page 79).

**Describe the Sebaceous Glands.** They are small, glandular bodies situated in the corium or in the subcutaneous cellular tissue over most of the body, but not in that of the palmar surface of the hands or the plantar surface of the feet. Each gland consists of a single sacculated duct opening into a hair follicle, but sometimes on the surface of the integument.

**State the probable number of Sweat-glands and their evaporating area.** They are estimated as varying in different parts of the integument, from 417 to 2800 to the square inch, giving for the whole body a total of nearly two millions and a half, representing an evaporating surface of about 8 square inches.

**Describe the Sweat-glands.** Each gland consists of a single convoluted tube, situated usually in the subcutaneous cellular tissue, and opening on the surface of the integument by a spiral duct which pierces the derma and the epidermis. It is formed of 2 coats, an external fibro-cellular, which is continuous with the corium, and an epithelial lining, continuous with the epidermis.

## THE TONGUE.

[The Tongue is described on page 13.]

**What are the special Organs of Taste?** The *Taste-buds*, small flask-shaped bodies, each about  $\frac{1}{800}$  inch long, situated in the fungiform and circumvallate papillæ of the tongue. The seat of the sense of taste lies, however, in the mucous membrane covering the dorsum of the tongue, the upper portion of the pharynx, the soft palate and the fauces.

**What are the special Nerves of Taste in the Tongue?** The—  
*Chorda Tympani Branch of the Facial*,—for its anterior two-thirds; perceiving saline, acid and styptic qualities (Flint).  
*Lingual Branch of the Glosso-pharyngeal*—for its posterior third; appreciating alkaline, metallic, sweet and bitter tastes (Flint).

**What is Sapolini's view of the Chorda Tympani Nerve?** From repeated dissections, Dr. Sapolini, of Milan, believes the chorda tympani to be a separate cranial nerve, having its proximal end in the so-called intermediary nerve of Wisberg, originating in the floor of the 4th ventricle,

and terminating in a dense plexus with the lingual branch of the 5th nerve, in the muscles of the tongue. He further concludes that the chorda tympani is the nerve governing the movements of the tongue in speech, and that the nerves of taste are the lingual branches of the 5th and 9th nerves.

## THE NOSE.

[For an osteological description of the Nasal Fossæ and Septum, see COMPEND OF ANATOMY, page 31.]

**Where is the Organ of Smell situated?** In the mucous lining of the upper portion of the nasal fossæ, which is the seat of distribution of the terminal filaments of the *Olfactory Nerve*,<sup>d</sup> the special nerve of the sense of smell.

**What is the Schneiderian Membrane?** The Schneiderian or Pituitary Membrane is

the mucous membrane of the nasal fossæ. It is continuous with the mucous lining of the pharynx, Eustachian tube, tympanum and mastoid cells; also with that of the frontal,<sup>a</sup> ethmoidal and sphenoidal sinuses,<sup>b</sup> the antrum, nasal duct, and the conjunctiva.

It is covered with columnar epithelium, ciliated through most of its extent, provided with mucous glands, and in its deeper layer with the—

*Olfactory Cells of Schultze*,—spindle-shaped epithelial structures, grouped around and between the columnar epithelial cells, and joined together by their anastomosing processes, to form an intricate plexus on which the terminal fibres of the olfactory nerve are supposed to be distributed.

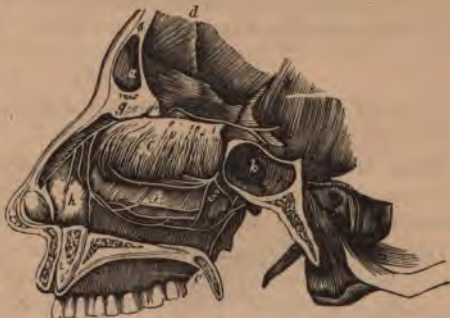**Name the Arteries of the Nose.** They are the—

*Lateralis Nasi*,—branch of the facial, to the alæ of the nose.

*Nasal of the Septum*,—from the superior coronary artery.

*Nasal*,—branches of the ophthalmic and infra-orbital.

FIG. 28.



**Name the Arteries of the Nasal Fossæ.** They are the—  
*Anterior and Posterior Ethmoidal*,—from the ophthalmic.  
*Spheno-palatine*,—branch of the internal maxillary.  
*Alveolar*,—br. of the int. maxillary, to the antrum.

**What Nerves supply the Nose?** Branches from the facial, infra-orbital and infra-trochlear, and a filament from the nasal branch of the ophthalmic nerve.

**What Nerves supply the Nasal Fossæ?** They are the—  
*Olfactory or 1st Cranial, e*—over the upper third of the septum nasi, and over the superior and middle turbinated bones.  
*Nasal Br. of the Ophthalmic, g*—to the septum and outer walls.  
*Ant. Dental Br. of Sup. Maxillary f*—to the inferior meatus of the nose and the inferior turbinated bone.  
*Spheno-palatine Ganglion*,—sends the *Vidian* to the septum and the superior turbinated bone,—the *Superior Nasal Br.* to the same parts,—the *Naso-palatine* to the middle of the septum,—and the *Anterior Palatine* to the middle and lower turbinated bones.

## THE EYE.

[For an osteological description of the Orbit, see COMPEND OF ANATOMY, page 29.]

**What is the Visual Apparatus?** It comprises the eyeballs and their appendages, which collect the luminous impressions,—and the optic nerves, which convey these impressions to the brain.

**Describe the Eyeball.** It is a spherical organ, situated in the anterior part of the orbital cavity, on a cushion of connective tissue and fat, where it is retained by its muscles, the optic nerve, the conjunctiva, etc., and protected in front by the eyelids and eyebrows. Projecting from its anterior surface is the segment of a smaller, transparent sphere, the *Cornea*. Its—

*Diameters*,—Antero-posterior, about .95 inch,—Transverse, .92 inch,—Vertical, .90 inch, in the adult.

*Anterior Pole*,—the geometric centre of the cornea.

*Posterior Pole*,—the geometric centre of the fundus.

*Optic Axis*,—an imaginary straight line connecting the poles.

*Visual Axis*,—an imaginary straight line from the yellow spot to the object, through the nodal point. It cuts the cornea above the optic axis at an angle therewith of 3° to 7°, the *Visual angle*.

*Nodal Point*,—the centre of curvature of refracting surfaces.

*Equatorial Plane*,—an imaginary plane through the centre of the eyeball, perpendicular to the axis, dividing the ball or globe into the anterior and posterior hemispheres. The *Equator* is the line where this plane cuts the surface of the globe.

*Meridional Planes*,—are imaginary planes coinciding with the axis of the eyeball. *Meridians* are the lines where these planes intersect the surface of the globe.

**Describe the Tunica Vaginalis Oculi.** It is a fibrous capsule, surrounding the eyeball and the intra-orbital portion of the optic nerve; arising from the optic foramen and being lost anteriorly on the sclerotic. It consists of two membranous layers enclosing a lymph-space which communicates with the lymph-space between the sclerotic and choroid coats. The tendons of the ocular muscles pierce it.

*Capsule of Bonnet*,—is the portion of the tunica vaginalis posterior to the passage of the tendons through it. This part is loosely attached to the eyeball, which rotates in it.

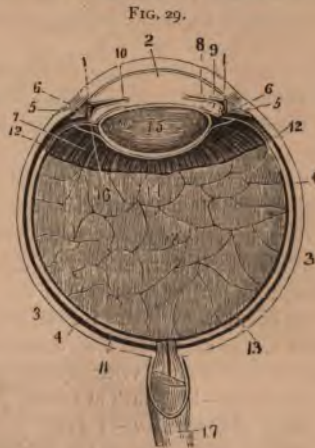*Capsule of Tenon*,—is the portion of the tunica vaginalis anterior to the passage of the tendons.

**Name the Tunics of the Eyeball.** They number 3, and are named as follows:—

1. *Sclerotic<sup>3</sup> and Cornea<sup>1</sup>*—externally protective.
2. *Uveal Tract*,—or vascular tunic, comprising the Choroid,<sup>4</sup> Ciliary body, and the Iris.<sup>5</sup>
3. *Retina<sup>11</sup>*—the innermost tunic, nervous.

**Name the Humors of the Eyeball.** They also number 3, as follows:—

1. *Aqueous<sup>2</sup>*,—in the anterior<sup>2</sup> and middle<sup>9</sup> chambers.
2. *Crystalline*,—forming the crystalline lens.<sup>15</sup>
3. *Vitreous<sup>13</sup>*,—in the posterior chamber of the eyeball.





## THE SCLEROTIC AND CORNEA.

**Describe the Sclerotic.** The Sclerotic or Hard coat is the posterior five-sixths of the external tunic of the eyeball, the anterior one-sixth being the Cornea. Externally it is of a white color, covered anteriorly by the conjunctival mucous membrane, posteriorly being continuous with the sheath of the optic nerve. Internally its color is brown, and its surface marked by grooves for the ciliary nerves. The optic nerve pierces it posteriorly, also the long and short ciliary arteries, posterior ciliary veins and short ciliary nerves. In the equatorial region it is pierced obliquely by the venæ vorticosæ, and around the corneal border by the anterior ciliary arteries and veins. It is composed of connective tissue with elastic fibres, intermixed with pigment cells, and cells resembling the corneal corpuscles. Its—

*Thickness*,— $\frac{1}{25}$  inch posteriorly,  $\frac{1}{50}$  inch anteriorly.

*Lamina Fusca*,—a layer of very fine connective tissue, connecting the sclerotic with the outer surface of the choroid.

*Lamina Cribosa*,—the posterior perforated portion of the sclerotic. The largest opening transmits the arteria centralis retinae, and is named the *porus opticus*.

*Sub-conjunctival Tissue*,—connects the conjunctiva with the outer surface of the sclerotic.

*Sulcus*,—a slight circular depression around the junction of the sclerotic with the cornea.

*Posterior Vascular Zone, or Zone of Zinn*,—an arterial zone around the optic nerve entrance, formed by twigs of the short ciliary going to the optic nerve to anastomose with branches of the central artery of the retina.

*Anterior Vascular Zone*,—around the cornea, formed by sub-conjunctival branches of anterior ciliary vessels.

*Nerves*,—probably none exist in the sclerotic.

**What is the Cornea?** The Cornea, or Horny body, is the anterior transparent projecting portion of the external tunic of the eyeball, forming about one-sixth thereof. It is set into the sclerotic as a watch-crystal into its case, is of ellipsoidal base, the transverse diameter being the longest, and slightly more convex vertically than horizontally. Its—

*Thickness*,—is  $\frac{1}{8}$  inch at centre,  $\frac{1}{22}$  inch at periphery.

*Index of Refraction*,—1.342.

*Vessels*,—none, except the peripheral zone,  $\frac{1}{5}$  inch wide, formed of capillary loops from episcleral branches of the anterior ciliary.

*Nerves*,—are numerous; 20 or 30 twigs from the ciliary nerves form an intricate plexus throughout the laminated substance.

**What is the Structure of the Cornea?** It consists of five layers,—the true corneal tissue, having in front an anterior elastic lamina and the conjunctival epithelium, behind a posterior elastic lamina and the epithelial lining of the aqueous chamber.

1. *Layer of Conjunctival Epithelium*  $\frac{1}{800}$  inch thick, consists of two or three layers of transparent nucleated cells.
2. *Anterior Elastic Lamina*,—also named the Membrane of Bowman or Membrane of Reichert,—is  $\frac{1}{3000}$  to  $\frac{1}{2300}$  inch thick, a firm, elastic and transparent homogeneous membrane, resisting most chemical agents.
3. *True Corneal Tissue*,— $\frac{1}{25}$  inch thick, a transparent fibrous structure formed of five connective-tissue fibrillæ, united in bundles, and these in laminae, between which is a semi-fluid cement, filled with *corneal corpuscles* and wandering cells.
4. *Posterior Elastic Lamina*,—or Membrane of Descemet, is, like the anterior elastic lamina, a structureless basement membrane. It is continuous at its margin with the ligamentum pectinatum of the iris.
5. *Posterior Epithelial Layer*,—a single layer of flattened, polygonal, transparent, nucleated cells, forming the endothelium of the membrane of Descemet.

#### THE UVEAL TRACT.

**Describe the Choroid.** It is the posterior portion of the middle tunic of the eyeball,  $\frac{1}{300}$  to  $\frac{1}{150}$  inch thick, and extends from the optic nerve entrance to the ora serrata, a little in front of the equator. It is highly vascular, of dark-brown color, connected to the sclerotic by the *lamina fusca* (see above), terminates anteriorly in the *Ciliary Processes*, and is composed of four layers, as follows:—

1. *Tunica Vasculosa*,—externally, consists of the venæ vorticosæ and the larger arterial branches.
2. *Membrana Ruyschiana, or Chorio-capillaris*,—the middle layer—consists of a fine capillary plexus.
3. *Limiting Membrane*, a structureless hyaline membrane, covering the inner surface of the capillary layer.
4. *Pigmentary Layer*, internally, a single layer of hexagonal nucleated cells, loaded with pigment of a brown-black color, which is absent in albinos, and of slight amount in blondes. [Considered by some anatomists the 10th layer of the retina.]

*Arteries of the Choroid*,—are the short posterior ciliary, and recurrent branches from long posterior and anterior ciliary.

*Veins*,—unite into 4 or 6 venæ varicosæ, which pass out through the sclerotic near its equator.

*Nerves*,—derived from 3d, 5th and sympathetic, through the long and short ciliary nerves.

**What are the Ciliary Processes?** They are 70 to 80 folds, formed by the anterior prolongation of the middle and internal layers of the choroid on the inner surface of the ciliary muscle, being received into corresponding folds on the suspensory ligament of the lens. They are about  $\frac{1}{8}$  inch in length, and form a curtain-like expansion behind the iris.

**Describe the Ciliary Body.** It is the portion of the uveal tract between the choroid and the iris, and consists of ciliary muscle covered by choroidal stroma and the ciliary processes. The—

*Ciliary Muscle or Muscle of Bowman*,—is a ring of involuntary muscular fibres, supplied by the 3d nerve; is thickest anteriorly, thin posteriorly. Its fibres arise from the corneo sclerotic junction, and pass backward to be attached to the choroid in front of the retina. Consists of meridional fibres drawing the choroid forward, and circular fibres which relax the zonula and permit the lens to become more convex, from its own elasticity.

*Annular Muscle of Müller*,—consists of separate circular bundles at the anterior internal angle of the ciliary body.

*Circulus Arteriosus Major and Minor*,—are arterial circles on the ciliary muscle, formed by branches of the long posterior ciliary and anterior ciliary arteries.

**What is the Iris?** It is a perforated curtain, suspended in the aqueous humor behind the cornea and in front of the lens, and is the anterior portion of the middle tunic of the eyeball, being continuous with the ciliary muscle and the choroid coat. It is about  $\frac{1}{8}$  inch wide,  $\frac{1}{8}$  inch thick, and is composed of radiating and circular muscular fibres, a fibrous stroma and pigment cells, covered by a layer of irregular cells continuous with those of the membrane of Descemet. The—

*Pupil*,—is the central opening in the iris, situated a little to the nasal side of the centre, diameter  $\frac{1}{2}$  to  $\frac{1}{4}$  inch.

*Ligamentum Pectinatum Iridis*,—or Dollinger's band,—is the suspensory ligament of the iris, connecting its ciliary margin with the corneo-sclerotic junction. It is formed of strong fibrous prolongations from the posterior surface of the cornea.

*Fontana's Spaces*,—are spaces between the prolongations which form the ligamentum pectinatum. In some animals, as the ox, they form regular canals.

*Uvea, or Tapetum*,—a layer of purple pigment-cells on the posterior surface of the iris, continuous with the pigment layer of the ciliary processes.

*Sphincter Pupillæ*,—a layer of circular muscular fibres around the pupillary margin, supplied by 3d nerve.

*Dilator Pupille*,—radiating muscular fibres from the pupillary margin toward the ciliary border, supplied by fibres of the sympathetic, from the ciliary ganglion.

*Membrana Pupillaris*,—a vascular membrane which covers the pupil in the fœtus, disappearing about the eighth month,—occasionally permanent.

*Arteries*,—are derived from the long and anterior ciliary, forming the *circulus major iridis* at the ciliary border, and the *circulus arteriosus iridis minor* near the pupillary margin.

*Veins*,—empty into those of the ciliary processes and the anterior ciliary veins.

*Sinus Circularis Iridis, Canal of Schlemm, or Canal of Fontana*,—is a minute canal at the corneo-sclerotic junction, extending around the circumference of the attached border of the iris. It is lined by endothelium and encloses a venous plexus, receiving veins from the sclerotic and the ciliary plexus. It communicates with the chamber of the aqueous humor and with the anterior ciliary veins.

*Nerves of the Iris*,—are derived from the 3d, 5th and the sympathetic, through the long and short ciliary nerves. The 3d supplies the circular fibres, the sympathetic the radiating ones, the 5th, nerves of common sensation.

#### THE RETINA.

**What is the Retina?** It is the innermost or nervous tunic of the eye, —a delicate, grayish, transparent membrane, about  $\frac{1}{75}$  of an inch thick at the fundus,  $\frac{3}{100}$  inch at the anterior margin. It is formed by a membranous expansion of the optic nerve elements, and extends from the termination of that nerve nearly as far forwards as the ciliary processes, terminating in a jagged margin, the *Ora Serrata*, though its fibrous stroma is continued over the ciliary body as the *Pars Ciliaris Retinæ*. The—

*Macula Lutea, or Yellow Spot*,—situated on the retina, exactly in the visual axis, is an elevated oval spot where vision is very acute, the

retina being very thin and full of nerve elements closely packed, at the expense of its connective tissue. No rods, no nerve-fibre layer, but the cones and ganglion cells are very numerous.

*Fovea Centralis*,—a depression at the centre of the macula lutea,  $\frac{1}{125}$  to  $\frac{1}{60}$  inch in diameter, in which the sense of vision is most acute.

*Optic Disc or Papilla*,—the point where the optic nerve escapes, the central artery of the retina piercing its centre. It lies about  $\frac{1}{10}$  inch internal to and  $\frac{1}{20}$  inch below the posterior pole of the eye, and is often called the *Blind Spot*, being the only part of the fundus oculi from which the power of vision is absent.

*Pars Ciliaris Retinae*,—the part of the retinal stroma which is prolonged over the ciliary body, and is destitute of nerve-elements.

*Arteries of the Retina*,—arise from the arteria centralis retinae (br. of ophthalmic) just behind the optic disc, run chiefly upward and downward, accompanied by veins, to terminate in capillary network. No vessels exist in the fovea centralis, and only the finest capillaries in the macula lutea.

**Describe the Structure of the Retina.** It is composed of nervous elements, blood-vessels, and modified connective tissue resembling the neuroglia of the brain, arranged in 9 layers, from without inwards, as follows, viz:—

1. *Rods and Cones, or Jacob's Membrane*,—the perceptive layer of the retina, composed of rods and cones closely packed together, like palisades, the termini, probably, of the optic nerve fibres.
2. *External Limiting Membrane*,—a membranous expansion of radial connective tissue, perforated by foramina.
3. *External Granular Layer*,—consists of ellipsoid cells, forming a nucleated enlargement of Jacob's membrane.
4. *External Molecular Layer*,—a very thin layer of fine granules and nerve-fibrillae.
5. *Internal Granular Layer*,—small round cells with large nuclei, their processes uniting with the ganglion cells.
6. *Internal Molecular Layer*,—fine granules intersected by finest nerve fibres and connective tissue elements.
7. *Ganglionic Layer*,—a very thin layer of large ganglion cells, having large nuclei and nucleoli, with branching processes to the optic nerve fibres of next layer.
8. *Optic Nerve Fibres*,—composed of the terminal fibres of the optic nerve radiating from the papilla in all directions. They consist of the axis-cylinder only.

9. *Membrana Limitans Interna*,—a perfectly transparent membrane, made up of the retinal connective tissue, and lining the inner surface of the retina.

A tenth layer is described by some anatomists,—the pigmentary layer of the choroid. [See *ante*, page 69.]

#### Name the Essential Elements of the Retinal Structure.

PRINCIPAL ELEMENTS, are the—

1. *Nerve-fibres*,—which in the molecular layers break up into very delicate plexuses. In their course are found—
2. *Nerve-cells*,—ordinary bipolar or multipolar, and modified ones, the so-called granular layers of the retina.
3. *Terminal Organs*,—the rods and cones of Jacob.

SUBORDINATE ELEMENTS, are the—

1. *Modified Connective Tissue*,—of spongy nature.
2. *Vessels*,—blood vessels and lymphatics.

#### THE HUMORS.

**What is the Aqueous Humor?** It is a clear, alkaline, serous fluid, composed of water, 96.7, albumen, .1, chloride of sodium and extractive matters, 3.2, weighing 4 to 5 grains, and filling the anterior and posterior aqueous chambers, which communicate with each other when the pupil is dilated sufficiently to remove the pupillary margin of the iris from the surface of the lens. The—

*Anterior Aqueous Chamber*,—has the cornea in front, and the iris behind.

*Posterior Aqueous Chamber*,—has the iris in front, the lens, zonula and ciliary body behind.

**Describe the Crystalline Lens.** It is a bi-convex, elastic, transparent body, enclosed in a capsule, held in place by a suspensory ligament, and situated between the posterior aqueous chamber and the chamber of the vitreous humor, immediately behind the pupil. Its posterior surface is the most convex, and rests in the *hyaloid fossa* of the vitreous. Its—

*Dimensions and Weight*,—diameter, about  $\frac{3}{8}$  inch,—axis about  $\frac{1}{2}$  inch,—weight, 4 to  $4\frac{1}{2}$  grains,—index of refraction, 1.44.

*Composition*,—water 60, soluble albuminous matter 35, insoluble albuminous matter 2.5, fat and cholesterine 2 per cent.

*Capsule*,—is transparent, elastic,  $\frac{1}{2000}$  inch thick anteriorly,  $\frac{1}{6000}$  inch posteriorly; has a layer of flat cells between its anterior portion and the lens, which, after death, break down into a fluid, the *Liquor Morgagni*.

*Zonula of Zinn, or Suspensory Ligament*,—connects the capsule with the ciliary body. It is formed by a splitting of the hyaloid membrane into two layers, one going in front of the lens, the other behind.— [See below.]

*Canal of Petit*,—is a triangular space around the circumference of the lens, formed by the separation of the two portions of the suspensory ligament.

*Processus Zonulæ*,—are small radiating folds on the anterior surface of the suspensory ligament, which are received between the ciliary processes.

**Describe the Structure of the Crystalline Lens.** It consists of flattened hexagonal fibres, united laterally into lamellæ, by serrated edges, and curving around the borders of the organ. Its centre or *Nucleus* is unstratified, and denser than the surrounding portion or *Cortex*. It is unorganized, having no vessels or nerves, but receives its nutriment by imbibition from the uveal tract, and possibly from the other humors of the eye.

**What is the Vitreous Humor?** The Vitreous Humor or Hyaloid Body is an apparently structureless substance, of gelatinous consistence, consisting of water with a little albumen and salts, and containing cells, nuclei, and connective-tissue filaments. It has no vessels or nerves, and is situated in the posterior chamber of the eye, behind the lens, which it supports, as also the retina. The—

*Canal of Stilling, Canal of Cloquet, or Hyaloid Canal*,—traverses the vitreous humor antero-posteriorly, being the channel for the transmission in the fœtus of the *hyaloid artery* to the *membrana pupillaris*. [See page 71.]

*Hyaloid Fossa*,—a depression on the anterior surface of the vitreous, receiving the posterior convexity of the lens.

**What is the Hyaloid Membrane?** It is a delicate capsule investing the vitreous, and thought to send delicate septa into the substance of that humor. It divides anteriorly into two layers, which enclose the Canal of Petit and the Lens, forming the suspensory ligament of the latter, or Zonula of Zinn. [See *ante*, this page.]

The above is the view of most anatomists, but some assert that this membrane is identical with the internal limiting membrane of the retina, extending only to the ora serrata. [Hænel, Iwanoff, etc.]

Others admit a hyaloid membrane surrounding the whole of the vitreous, but deny that it splits to enclose the lens, and assign but one layer to the suspensory ligament, namely, that in front of the Canal of Petit.

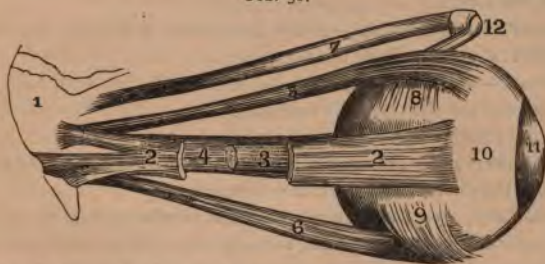**Name the Muscles of the Eyeball.** They number 6, of which 4 are *recti* and 2 *oblique*, as follows,—

*Rectus Superior*,<sup>5</sup>—from the upper margin of the optic foramen and the sheath of the optic nerve,—into the sclerotic coat. *Action* to rotate the eyeball upwards. *Nerve*, 3d cranial.

*Rectus Inferior*,<sup>6</sup>—from the ligament of Zinn,—into the sclerotic coat. *Action*, rotates the eyeball downwards. *Nerve*, 3d cranial.

*Rectus Internus*,<sup>4</sup>—from the ligament of Zinn,—into the sclerotic coat. *Action*, rotates the eyeball inwards. *Nerve*, 3d cranial.

FIG. 30.



*Rectus Externus*,<sup>2</sup>—by two heads, the upper from the outer margin of the optic foramen, the lower from the ligament of Zinn and a bony process at lower margin of the sphenoidal fissure,—into the sclerotic coat. *Action*, to rotate the eyeball outwards. *Nerve*, 6th cranial, or abducens. Between the two heads of the external rectus pass the 3d, nasal branch of the 5th, and the 6th cranial nerves, and the ophthalmic vein.

*Obliquus Superior*,<sup>7</sup>—from about a line above the inner margin of the optic foramen, its tendon passing through a "pulley"<sup>12</sup> near the internal angular process of the frontal bone and thence beneath the rectus superior,—into the sclerotic coat, at right angles to the insertion of the rectus superior. *Action*, to rotate the eyeball on its antero-posterior axis. *Nerve*, 4th cranial, or patheticus.

*Obliquus Inferior*,<sup>9</sup>—from the orbital plate of the superior maxillary,—into the sclerotic coat below the insertion of the external rectus and at right angles thereto. *Action*, to rotate the eye on its antero-posterior axis. *Nerve*, 3d cranial.

**What Nerves supply the Muscles of the Eye?** The—

3d Cranial or *Motor Oculi*,—supplies the superior, inferior and internal recti, and the inferior oblique.

4th Cranial, or *Trochlear*,—supplies the superior oblique.

6th Cranial, or *Abducens*,—supplies the external rectus.



**Describe the Arteries of the Eye.** The Eye is supplied by the *Ophthalmic* and *Anterior Cerebral* branches of the Internal Carotid artery, and the *Infra-orbital* branch of the Internal Maxillary (from the External Carotid). The—

**OPHTHALMIC**,—arises from the cavernous portion of the Internal Carotid, enters the optic foramen, giving off the—

*Lachrymal*,—to the lachrymal gland, the upper eyelid, and the conjunctiva, anastomosing with the palpebral arteries.

*Supra-orbital*,—supplies the superior rectus and levator palpebræ muscles, the forehead and pericranial tissues.

*Ant. and Post. Ethmoidal*,—to the dura mater, the nose, the anterior ethmoidal cells, and the frontal sinus.

*Palpebral*,—superior and inferior,—to the eyelids.

*Frontal*,—to the tissues of the forehead.

*Nasal*,—to the lachrymal sac, and the nose.

*Short Ciliary*, 12 or 15,—pierce the sclerotic at the lamina cribosa, supplying the choroid and the ciliary processes.

*Long Ciliary*, 2,—pierce the sclerotic, and pass forwards between it and the choroid, to supply the iris, forming two arterial circles thereon.

[See page 71.]

*Anterior Ciliary*,—arise from the muscular branches, pierce the sclerotic, and join the great arterial circle of the iris.

*Arteria Centralis Retinae*,—pierces the optic nerve obliquely, and is distributed to the retina. [See page 72.]

*Muscular Branches*, 2,—superior and inferior, supply the muscles of the eyeball.

**ANTERIOR CEREBRAL**,—branch of the Internal Carotid,—sends nutrient capillaries to the optic nerve.

**INFRA-ORBITAL**,—branch of the Internal Maxillary artery, sends branches to the inferior rectus and inferior oblique muscles, and to the lachrymal gland.

**Name the principal Lymph-spaces of the Eyeball.** The—

*Canal of Schlemm*,—around the circumference of the iris.

*Peri-choroidal Space*,—between the choroid and the sclerotic.

*Space of Tenon*,—between the globe and its capsule.

*Vaginal Spaces*,—between the sheaths of the optic nerve.

**What Veins has the Eye?** It has 2 main trunks, the *Superior* and *Inferior Ophthalmic Veins*, which empty into the cavernous sinus, after collecting the blood from the smaller venous channels. The veins of the

eye anastomose freely with the facial veins, thus permitting the escape of venous blood in either direction.

**Name the Nerves of the Eye.** They are the—

*Nerve of Special Sense*,—the Optic, or 2d cranial nerve.

*Motor Nerves*,—the 3d, 4th, 6th, filaments of the 5th, and some fibres from the sympathetic.

*Sensory Nerve*,—the Ophthalmic Division of the 5th, giving off the—

Lachrymal.					
Frontal,	{	Supra-trochlear.	Naso-ciliaris.	{	Ganglionic.
		Supra-orbital.			Long Ciliary.
					Infra-trochlear.

*Sympathetic Branches*,—arise from the medulla, cilio-spinal region, cavernous and carotid plexuses, and join the 3d, 4th, 5th, and 6th nerves, sending filaments to the dilator fibres of the iris, to the muscles of the orbit and lids, to the ciliary ganglion, and to the walls of the arteries.

*Short Ciliary*,—some 20 in number, arise from the *Ciliary Ganglion* (see COMPEND OF ANATOMY, page 137), pierce the sclerotic and go to the ciliary muscle, choroid, iris, cornea, and to the sheath of the optic nerve.

*Ascending*,—from Meckel's ganglion (see COMPEND OF ANATOMY, page 137), enter the orbit by the spheno-maxillary fissure, going to the optic nerve, the 6th nerve, and the Ciliary ganglion.

**Describe the formation and course of the Optic Tract.** The

fibres which form the optic tract have their deep origin in the optic thalamus, corpora geniculata, and the anterior corpora quadrigemina. The tract winds around the crus cerebri<sup>7</sup> as a flattened band, receiving from the crus a few fibres of attachment, and also fibres from the lamina cinerea and the tuber cinereum. In front of the latter body the two tracts join to form the *Optic Commissure* or *Chiasm*.<sup>2</sup>

**What is the arrangement of the Fibres in the Optic Commissure?** As generally described, the fibres undergo a partial decussation, as follows, viz.—



*Decussating fibres*,—are the most numerous. They lie in the centre of the commissure, and pass across to the opposite side, connecting the retina of each eye with the opposite cerebral hemisphere.

*Longitudinal Fibres*,—are the external fibres in the optic tracts, passing into the optic nerve of the same side, connecting each retina with the cerebral hemisphere of its own side.

*Inter-cerebral Fibres*,—situated posteriorly in the commissure, passing from one optic tract to the other.

*Inter-retinal Fibres*,—lie anteriorly in the commissure, passing from one optic nerve to the other, and connecting the retina of one eye with that of the other.

**Describe the Optic Nerve.** The Optic Nerve proper is the 2d cranial nerve, arises from the optic commissure, passes into the orbit by the optic foramen in company with the ophthalmic artery, is pierced by the central artery of the retina, and enters the eyeball posteriorly  $\frac{1}{16}$  inch inwardly from its axis, piercing the sclerotic and choroid coats, and finally expanding in the retina. It is surrounded by a tubular process of dura mater, which as the nerve enters the orbit, subdivides to form both the sheath of the nerve and the periosteum of the orbit.

#### APPENDAGES OF THE EYE.

**What are the Tutamina Oculi?** They are the appendages of the eye, including the—

*Eye-brows*, or Supercilia.

*Lachrymal Gland*, and *Ducts*.

*Eye lids*, or Palpebræ.

*Lachrymal Sac*.

*Conjunctiva*.

*Nasal Duct*.

**What are the Eyebrows?** They are arched elevations of the integument over the supra-orbital arches, are covered with a row of short hairs, and are drawn downwards and inwards by the *corrugator supercilii* muscle. [See COMPEND OF ANATOMY, page 68.]

**Describe the Eyelids.** The Palpebræ, or Eyelids, are two thin, movable folds, placed in front of the eye, for its protection. The upper lid is the most movable one, having its own levator muscle, the *Levator palpebræ superioris*. [See COMPEND OF ANATOMY, page 68.] The—

*Palpebral Fissure*,—is the space between their free margins, its outer and inner angles being termed respectively the *External Canthus* and *Internal Canthus*.

*Lacus Lachrymalis*,—is a small triangular space at the internal canthus, between the lids and the globe.

*Lachrymal Papilla*,—on the edge of each lid, about  $\frac{1}{4}$  inch from the internal canthus.

*Punctum Lachrymale*,—a minute orifice on the papilla, and the beginning of the lachrymal canal.

**What is the Structure of the Eyelids?** They are composed externally of skin, internally of mucous membrane (the palpebral conjunctiva), and between these lie areolar tissue, the orbicularis muscle, tarsal cartilage, fibrous membrane, Meibomian glands, vessels and nerves. The—

*Orbicularis Palpebrarum Muscle*,—is very thin and pale. [See COMPEND OF ANATOMY, page 68.]

*Tensor Tarsi, or Horner's Muscle*,—[See COMPEND OF ANATOMY, page 68] is a portion of the orbicularis.

*Tarsal Cartilages*,—are plates of fibro-cartilage, forming the framework of the lids. The upper one is crescentic in shape, the lower one elliptical and smaller.

*Tarsal Ligaments*,—are fasciæ connecting the tarsal cartilages to the circumference of the orbit. Externally they connect with the malar bone, and are there called the *External Canthal Ligaments*.

*Tendo Oculi*,—connects the inner end of each tarsal cartilage to the nasal process of the superior maxillary bone.

*Meibomian Glands*,<sup>1</sup>—are sebaceous glands imbedded in the tarsal cartilages, 30 to 40 in the upper lid, 20 to 30 in the lower one. They open along the inner edge of the free border of each lid, and furnish a sebaceous secretion, to prevent adhesion of the lids

*Eye-lashes, or Cilia*,—are a double or triple row of short hairs, situated on the free margins of the lids; their follicles lying in the connective tissue beneath the tarsal cartilages.

*Arteries*,—are the *Palpebral* branches of the ophthalmic artery, forming the *Superior and Inferior Tarsal Arches*, and anastomosing with the angular, anterior temporal, lachrymal and transverse facial.

*Nerves*,—the 3d, facial and sympathetic to the muscles; the 5th to the skin and conjunctiva.

**What is the Conjunctiva?** It is the mucous membrane which lines the eyelids, and is reflected over the front of the sclerotic and cornea. ∞

FIG. 37.



is continuous with the mucous lining of the Meibomian glands, canaliculi, lachrymal sac, nasal duct, lachrymal duct and gland. The—

*Palpebral Conjunctiva*,—consists of connective tissue covered by epithelium, is traversed by furrows, and has papillæ and follicular glands.

*Ocular Conjunctiva*,—is very thin and transparent, loosely attached on the sclerotic, firmly adherent over the cornea, where it has no vessels in its structure. It has very few papillæ, and no glands.

*Retro-tarsal or Palpebral Folds*,—superior and inferior,—are where the conjunctiva is reflected over the globe. They contain prominent papillæ, and conglomerate glands, called the accessory lachrymal glands.

*Plica Semilunaris, or Semi lunar Folds*,—a crescentic fold of conjunctiva at the inner canthus, considered the rudiment of the *membrana nictitans* or 3d eyelid of birds.

**What is the Caruncula Lachrymalis?** It is a small, red, conical body, situated in the lacus lachrymalis, at the inner canthus of the eye; consisting of hair follicles and sebaceous glands, and covered by conjunctiva. It is connected by tendinous fibres to the Capsule of Tenon and to the rectus internus muscle.

**Name the parts constituting the Lachrymal Apparatus.** They are the lachrymal gland and its ducts, the accessory conjunctival glands, the canaliculi, lachrymal sac, and nasal duct.

**Describe the Lachrymal Gland.** It is an oval gland situated in a fossa of the orbital portion of the frontal bone, at the outer angle of the orbit, its inferior surface resting on the eyeball, its lower margin or lobe being covered by conjunctiva. The—

*Tarso-orbital Fascia*,—connects the lachrymal gland to the bony roof of the orbit.

*Ducts*,—6 to 12 in number; open on the upper and outer portion of the palpebral conjunctiva.

*Secretion*,—tears,—lubricates the anterior surface of the eyeball. Excess evaporates, or collects in lacus and passes through puncta into canaliculi, and so to lachrymal sac, and thence, by the nasal duct, into the inferior meatus of the nose.

**What are the Canaliculi?** They are two minute canals,  $\frac{1}{3}$  inch in diameter and  $\frac{1}{2}$  inch long, which extend from the punctum in each lid to the lachrymal sac. They are lined with mucous membrane, and enveloped by fibres of the tensor tarsi muscle.

**Describe the Lachrymal Sac.** It is the superior dilated extremity of the nasal duct, and is situated in the groove formed by the lachrymal bone

and the nasal process of the superior maxillary. Its form is oval, flattened antero-posteriorly; its dimensions about  $\frac{2}{3}$  inch long and  $\frac{1}{2}$  inch wide. Its fundus is crossed by the tarsal ligament, and by the tensor tarsi muscle. Its junction with the nasal duct may be interrupted by folds of the lining mucous membrane.

**What is the Nasal Duct?** A membranous canal extending from the lachrymal sac to the inferior meatus of the nose. It is about  $\frac{3}{4}$  inch long,  $\frac{1}{8}$  inch in diameter, is contained in the osseous lachrymal canal, curving downwards, backwards and outwards, and its calibre is narrowest about its middle. Its mucous lining is thick, and continuous with the Schneiderian membrane of the nasal cavity. Surrounding it is a vascular network of connective tissue, and outside this, a tendinous sheath. At its lower end a fold of mucous membrane forms an imperfect valve.

### THE EAR.

**What Bone contains the Auditory Apparatus?** The petrous and mastoid portions of the Temporal bone. [Described in COMPEND OF ANATOMY, page 16.]

**Name the Divisions of the Auditory Apparatus.** The organ of hearing consists of the following parts, viz.—

- |  |   |                                 |
|--|---|---------------------------------|
| 1. <i>External Ear</i> .....             | { | <i>Auricle, or Pinna.</i>       |
|  | { | <i>External Auditory Canal.</i> |
|  | { | <i>Membrana Tympani.</i>        |
| 2. <i>Middle Ear or Tympanum</i> .....   | { | <i>Cavity of the Tympanum.</i>  |
|  | { | <i>Mastoid Cells.</i>           |
|  | { | <i>Eustachian Tube.</i>         |
|  | { | <i>Vestibule.</i>               |
| 3. <i>Internal Ear, or Labyrinth</i> ... | { | <i>Semicircular Canals.</i>     |
|  | { | <i>Cochlea.</i>                 |
|  | { | <i>Auditory Nerve.</i>          |

### THE EXTERNAL EAR.

**Describe the Auricle.** The Auricle or Pinna is the external irregularly-shaped appendage, fastened to the malar and temporal bones by elastic fibres. It consists of a broad plate of yellow cartilage, deficient in places where its parts are joined together by ligamentous tissue, and is covered by perichondrium and integument, the latter containing sebaceous and sweat glands, and provided with short, downy hairs. The Auricle presents several elevations and depressions, named as follows,—

*Concha*,—the central cavity leading into the canal.

*Tragus*,—a conical eminence in front of the concha, usually covered with hairs along its inferior border.

*Antitragus*,—a similar projection facing the tragus, from which it is separated by a deep fissure, the *Incisura intertragica*.

*Helix*,—the outer curved edge of the pinna, beneath which is a deep groove, the *Fossa navicularis*.

*Anti-helix*,—a curved ridge along the posterior boundary of the concha, bifurcating above to enclose a triangular depression, the *Fossa triangularis*.

*Lobe, or Lobule*,—the soft, pendulous portion, composed of integumentary, adipose and connective tissues.

**Name the Muscles of the Auricle.** The—

EXTRINSIC MUSCLES are the—

*Attollens Aurem, Attrahens Aurem, Retrahens Aurem.*

[These muscles are described in COMPEND OF ANATOMY, page 68.]

INTRINSIC MUSCLES are but slightly developed. They are the—

*Tragicus*,—lies vertically on the outer surface of the tragus.

*Anti-tragicus*,—on the posterior wall of the auditory canal.

*Helicis Major*,—vertically on the anterior border of the helix.

*Helicis Minor*,—on lateral surface of the root of the helix.

*Transversus Auriculæ*,—on the posterior surface of the auricle, radiating outwards from the convexity of the concha.

*Obliquus Auriculæ*,—also on the posterior surface, radiating upwards from the convexity of the concha.

*Dilator of Concha*,—on the tragus.

**Name the Arteries and Nerves of the Auricle.** The—

ARTERIES,—are the—

*Posterior Auricular*,—branch of the external carotid.

*Anterior Auricular*,—branch of the temporal.

*Auricular*,—branch of the occipital.

NERVES,—are the—

*Auriculus Magnus*,—from the cervical plexus.

*Posterior Auricular*,—from the facial nerve.

*Auricular*,—branch of the pneumogastric.

*Auriculo-temporal*,—branch of the inferior maxillary.

**Describe the External Auditory Canal.** It is an osseo-cartilaginous tube, about  $1\frac{1}{4}$  inch long, extending from the concha to the membrana tympani, and curved irregularly in its course. The cartilaginous, or exter-

nal portion, is about  $\frac{1}{2}$  inch long, and deficient posteriorly and above, where it is filled by strong fibrous tissue. The canal is lined with integument, having numerous hair follicles, sebaceous and ceruminous glands.

*Sulcus Tympanicus*,—a groove at the bottom of the canal for the insertion of the membrana tympani.

*Segment of Rivinus*,—at upper part of the sulcus tympanicus, each end having an osseous spine, the *Spina tympanica major and minor*.

**What are the Relations of the External Auditory Canal?** *In front*, the articulation of the lower jaw; *below and in front*, the parotid gland; *behind*, the mastoid cells and the transverse sinus; *above*, the mastoid cells and the dura mater of the brain.

**Name its Vessels and Nerves.** Its—

*Arteries*,—are branches of the posterior and deep auricular.

*Nerves*,—are chiefly derived from the temporo-auricular branch of the inferior maxillary division of the 5th nerve.

#### THE MEMBRANA TYMPANI.

**What is the Membrana Tympani?** The Membrana Tympani, or Drumhead, is an oval, inelastic, semi-transparent membrane, about  $\frac{1}{25}$  inch in thickness, situated obliquely at the bottom of the external auditory canal, which it separates from the cavity of the tympanum. Seen through the canal, it is of a delicate blue-gray color, arched inwards, and presenting a—

*Tubercle*,—white in color at the upper border, made by the short process of the malleus.

*Stripe*,—also white, running downwards from the tubercle, formed by the handle of the malleus.

*Light-spot*,—a triangular reflection, its apex at the tip of the malleus-handle, its base extending to the periphery of the membrane. It is due to the concavity of the drumhead.

*Umbo*,—or shadow, is the darker central portion.

*Shrapnell's Membrane*,—is the upper and posterior part of the drumhead, where it is somewhat flaccid.

*Rivinian Foramen*,—a minute opening supposed to exist in the portion called Shrapnell's membrane.

**In what direction is the Membrana Tympani situated?** Obliquely inwards and forwards, almost forming a continuation of the anterior wall of the external auditory canal.



**Describe the Structure of the Membrana Tympani.** It is composed of 3 layers, as follows:—

*External, or Dermoid Layer,*—continuous with the integument lining the external auditory canal.

*Middle Layer, or Lamina Propria,*—formed of outer radiating fibres, and inner circular ones. Between these two sets of fibres are situated the short process and handle of the malleus.

*Internal or Mucous Layer,*—is continuous with the mucous lining of the tympanum.

*Tendinous Ring,*—surrounds the margin of the membrane, being received into the sulcus tympanicus. (See page 83.)

**What Structures are presented by its Internal Surface?** A fibrous fold descends from the upper portion of the marginal ring, for a short distance along the malleus-handle, forming the—

*Anterior and Posterior Pouches*—one on each side of the malleus-handle, opening downwards.

*Tendinous Bands,* 4 or 5,—converge from the posterior margin to the middle of the malleus-handle.

**What Arteries supply the Membrana Tympani?** The—

*Deep Auricular,*—branch of the Internal Maxillary (Von Trölsch, Roosa etc.), supplies the external layer, and forms with the tympanic branches a capillary plexus in the middle layer.

*Tympanic,*—branches of the Internal Maxillary and Internal Carotid arteries, supply the internal layer, and anastomose on the membrana tympani with the—

*Vidian and Stylo-mastoid,*—branches respectively of the Internal Maxillary and the Posterior Auricular arteries.

**What Nerves supply the Membrana Tympani?** The external layer contains filaments from the Superficial Temporal branch of the 5th; the inner layer is supplied by the tympanic plexus.

#### THE TYMPANUM.

**Describe the Tympanum.** The Tympanum, Drum, or Middle Ear, is an irregularly-shaped cavity lying between the membrana tympani and the internal ear, and communicating with the pharyngeal cavity by the Eustachian tube. It contains the ossicles of the tympanum, part of the chorda tympani nerve, and air. Its average diameters are about  $\frac{1}{2}$  inch antero-posteriorly,  $\frac{1}{3}$  to  $\frac{2}{3}$  inch vertically, and  $\frac{1}{2}$  to  $\frac{3}{4}$  inch transversely.

**Name the Points on each wall of the Tympanum.** Its—

**ROOF**,—is very thin, and corresponds to a depression on the anterior surface of the petrous portion of the temporal bone.

**FLOOR**,—a thin plate, separating it from the jugular fossa and vein.

*Opening for Jacobson's nerve*,—in the floor.

**OUTER WALL**,—formed by the *membrana tympani* and presents—

*Iter Chordæ Posterioris*,—opens close to posterior edge of drumhead, for the entrance of the chorda tympani nerve.

*Iter Chordæ Anterioris, or Canal of Hugier*,—opening just in front of the drumhead, for the exit of the chorda tympani.

*Glaserian Fissure*,—opens above and in front of the drumhead, receiving the long process of the malleus, the anterior ligament of the malleus, and the tympanic artery.

**INNER WALL**,—is the outer wall of the labyrinth ;—presents—

*Fenestra Ovalis*,—an oval opening, leading into the vestibule, and closed by a membrane, to which is attached the base of the stapes.

*Fenestra Rotunda*,—a smaller opening, below the fenestra ovalis, leading into the scala tympani of the cochlea, and closed by the *membrana tympani secundaria*.

*Promontory*,—an elevation corresponding to the first turn of the cochlea, situated between the fenestræ and in front of them.

*Ridge of the Aqueductus Fallopii*,—above and behind the fenestra ovalis.

*Pyramid*,—a conical eminence containing a canal which communicates with the aqueductus Fallopii and encloses the stapedius muscle.

**ANTERIOR WALL**,—presents the—

*Opening of Canal for the Tensor Tympani Muscle*,—above, situated on a small projection, the *Anterior Pyramid*.

*Opening of the Eustachian Tube*,—next below. These two canals being separated by a bony lamina, the *Septum Tubæ*.

*Processus Cochleariformis*,—the small projecting end of the septum tubæ.

**POSTERIOR WALL**, separates it from the mastoid cells, presenting—

*Openings of the Mastoid Cells*.

**Describe the Ossicles of the Tympanum.** They are 3 small bones, which form a chain across the tympanic cavity, connecting the *membrana tympani* with the fenestra ovalis, and named the—

*Malleus, or Hammer, a*—consists of a head, neck, short process, long process, or *processus gracilis*, and handle, or *manubrium*. The short process and handle are fastened to the middle layer of the drumhead. The long process is received into the Glaserian fissure, and the head articulates with the head of the Incus.

FIG. 33.



*Incus, or Anvil, b*—has a head, a long and a short process. The head articulates with the head of the Malleus, the short process with the posterior wall of the tympanum, the long process with the head of the Stapes, by the *os orbiculare, c* its convex extremity.

*Stapes, or Stirrup, d*—presents a head, neck, base and crura. Its head articulates with the Incus, its base rests on the membrane closing the fenestra ovalis, its neck receives the tendon of the stapedius muscle.

**Name the Ligaments of the Ossicles.** They are the—

*Ligamentum Mallei Anterius*,—from the spina tympanica major to the neck and long process of the malleus.

*Lig. Mallei Externum*,—from the border of the Rivinian segment to the neck of the malleus. Its posterior fibres are the—

*Lig. Mallei Posticum*,—(*Laxator tympani minor* muscle of Sömmering)—is simply the posterior group of fibres of the preceding ligament.

*Lig. Mallei Superius*,—(*Suspensory lig. of the malleus*)—from the roof of the tympanum to the head of the malleus.

*Lig. Incudis Superius*,—from the roof of the tympanum to the head of the incus (Arnold.)

*Lig. Incudis Posticum*,—from the posterior wall of the tympanum to the short process of the incus.

*Lig. Obturatorium Stapedium*,—a thin membrane which closes the opening between the crura of the stapes.

*Annular Ligament*,—connecting the base of the stapes to the margin of the fenestra ovalis.

*Capsular Ligaments*,—around the articulations between the ossicles themselves, which articulations are lined by synovial membranes, with articular cartilages between the contiguous surfaces.

**Name the Muscles of the Tympanum.** Three are usually described,—the *Tensor tympani*, *Laxator tympani*, and the *Stapedius*. A fourth, the *Laxator tympani minor*, is now generally omitted, being considered

the posterior ligament of the malleus by most writers. Many otologists omit the *Laxator tympani* from the list also. [These muscles are described in *COMPEND OF ANATOMY*, page 71.]

**What Arteries supply the Tympanum? The—**

*Tympanic*,—branch of the Internal Maxillary, entering by the Glaserian fissure, anastomosing on the *membrana tympani* in a vascular circle, with the *Stylo-mastoid* and *Vidian* arteries, and the *Tympanic br.* of the Internal Carotid.

*Stylo-mastoid*,—br. of the Posterior Auricular, entering at the *stylo-mastoid foramen*.

*Petrosal*,—br. of Middle Meningeal artery, entering by the *hiatus Fallopii*.

*Tympanic*,—br. from the Internal Carotid artery.

*Vidian*,—br. of the Internal Maxillary artery.

*Branches*,—from the Ascending Pharyngeal artery.

**Name the Nerves of the Tympanum. The—**

*Tympanic Br. of the Glosso-pharyngeal* (Jacobson's Nerve),—enters the tympanum through its floor, and supplies the two *fenestræ* and the mucous lining of the cavity, helping to form the *tympanic plexus* (see below.)

*Tympanic Branch of the Facial Nerve*,—to the *stapedius* and *laxator tympani* muscles.

*Branch from the Otic Ganglion*,—to the *tensor tympani* muscle. [This ganglion is described in *COMPEND OF ANATOMY*, page 137.]

*Chorda Tympani Br. of the Facial*,—enters the tympanum by the *iter chordæ posterius*, crosses the cavity between the handle of the malleus and the long process of the incus, and makes its exit by the *iter chordæ anterioris*, after passing close along the upper part of the *membrana tympani*.

**How is the Tympanic Plexus Formed? By the—**

*Tympanic Br. of the Glosso-pharyngeal*,—or Jacobson's nerve.

*Branch*,—of the Superficial Petrosal, entering from above.

*Branches*,—from the Carotid plexus of the Sympathetic, through the wall of the carotid canal.

The plexus lies in grooves on the inner wall around the promontory, and supplies the mucous membrane of the tympanum.

THE EUSTACHIAN TUBE.

**What is the Eustachian Tube?** It is an osseo-cartilaginous canal about  $1\frac{1}{2}$  inches long,  $\frac{1}{2}$  inch in diameter at tympanic end,  $\frac{1}{3}$  inch at pharyngeal, which leads downwards and forwards from the tympanic cavity

into the pharynx. Of its length two-thirds is cartilaginous, one-third osseous. Above its bony portion is the canal for the tensor tympani muscle, from which it is divided by an osseous lamina, the *Septum tube*. Its—

*Cartilaginous Portion*,—consists of two plates of cartilage, their non-approximated edges being connected by a membrane.

*Pharyngeal Orifice*,—is trumpet-shaped, and situated in the posterior nasal space, just above the nasal floor.

*Mucous Membrane*,—covered with ciliated epithelium, and continuous with that of pharynx and tympanum.

**Name the Muscles of the Eustachian Tube.** They are the—

*Spheno-salpingo-staphylinus*,—the abductor or dilator of the tube—arises from the sphenoid bone and the cartilage of the tube, and is inserted into the convex border of the outer cartilage for its whole length.

*Nerve*,—internal pterygoid.

*Levator Veli Palati*,—from the temporal bone and the cartilage of the tube,—into the osseous tube, the cartilage, and the mucous membrane.

*Action*, to enlarge the transverse diameter. *Nerve*, pneumogastric.

*Salpingo-pharyngeus*,—a thin layer disposed along the median cartilaginous plate and the mucous membrane. *Action*, to fix the median cartilage. Called a fascia by some anatomists.

**What Arteries supply the Eustachian Tube?** The—

*Ascending Pharyngeal*,—branch of the External Carotid.

*Middle Meningeal*,—branch of the Internal Maxillary.

*Branch*,—from the Internal Carotid artery.

**Name its Nerves.** Besides those which supply the muscles of the tube (see above), it has branches from the—

*Superior Pharyngeal.*

*Glosso-pharyngeal.*

#### THE INTERNAL EAR.

**Name the Parts comprised in the Internal Ear.**

*Osseous Labyrinth*..... { *Vestibule.*  
  { *Semicircular Canals.*  
  { *Cochlea.*

*Membranous Labyrinth* { *Utricle.*  
  { *Membranous Semicircular Canals.*  
  { *Sacculæ.*  
  { *Membranous Cochlea.*

*Auditory Nerve*,—Portio Mollis of the 7th.

*Organ of Corti*,—the terminal auditory apparatus.

*Internal Auditory Canal*,—by which the auditory nerve enters.

Describe the general arrangement of the Internal Ear. It lies internal to the tympanum, within the petrous portion of the temporal bone, and consists of a series of osseous chambers, the *Osseous Labyrinth*, containing a fluid, the *Perilymph*, or *Liquor Cotunnii*, in which lies a membranous reproduction of the chambers, the *Membranous Labyrinth*, which also contains a fluid, the *Endolymph*, or *Liquor Scarpæ*. Upon the membranous labyrinth are distributed the terminal filaments of the auditory nerve, which being suspended between two fluids, are not only protected from injury, but enabled to perceive the most delicate vibrations which may be communicated to the fluids.

Describe the Vestibule. It is the common cavity of communication between the osseous parts of the internal ear, measures in vertical diameter, about  $\frac{1}{8}$  inch, laterally about  $\frac{1}{10}$  inch. It communicates in front with the scala vestibuli of the cochlea; and behind, by five openings, with the semicircular canals.

FIG. 34.

*Fenestra Ovalis*,—on its outer wall, closed by the base of the stapes and its annular ligament.

*Fovea Hemispherica, b*,—a small circular depression on the inner wall, for the saccule.

*Macule Cribosæ*,—are groups of very minute orifices on the inner wall, admitting the nerve-filaments.

*Crista, or Pyramidal Eminence*,

—a vertical ridge on the inner wall, bounding the fovea posteriorly.

*Aqueductus Vestibuli, d*—opens behind the crista, ending on the posterior surface of the petrous portion of the temporal bone. It contains a small blind canal opening by two arms, one into the utricle, the other into the saccule; also a small vein.

*Fovea Semi-elliptica, a*—a small oval depression on the roof, above and behind the fovea hemispherica. It lodges the utricle, and presents a *macula cribosa* for the entrance of branches of the vestibular nerve.

What are the Semicircular Canals? They are three C-shaped bony tubes, each about  $\frac{1}{20}$  inch in diameter, situated above and behind the vestibule, into which they open by 5 apertures. Each canal lies at a right angle with the other two. The



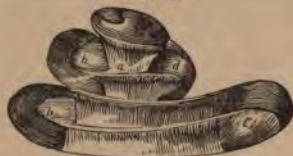*Superiore and Posterior Canals*,—are each nearly 1 inch long, vertically placed, joined together posteriorly where they open into the vestibule by a common orifice.<sup>c</sup>

*External Canal, s*,—is  $\frac{1}{2}$  inch long, horizontally placed, and directed outwards and backwards.

*Ampulla*,—is a flask-shaped dilatation of each canal at one extremity, having a diameter of about  $\frac{1}{10}$  inch.

**Describe the Cochlea.** The Cochlea is a bony tube about  $1\frac{1}{2}$  inch long, tapering from  $\frac{1}{10}$  to  $\frac{1}{20}$  inch in diameter, coiled around a central conical axis for  $2\frac{1}{2}$  turns, and resembling a snail-shell in appearance. It measures about  $\frac{1}{4}$  inch in length and the same in breadth at the base. It is situated in front of the vestibule, its apex pointing forwards and outwards, and is separated from the carotid canal in front by a thin wall. Its—

FIG. 35.



apex is within the last coil of the cochlea, and is expanded into a funnel-shaped lamella, the *Infundibulum*.

*Modiolus, a*—is the central axis, conical in shape, channeled by small canals for the passage of arteries and nerves, and by a central one, the *Canalis centralis modioli*. Its

apex is within the last coil of the cochlea, and is expanded into a funnel-shaped lamella, the *Infundibulum*.

*Lamina Spiralis, b*—is a thin osseous plate, projecting from the modiolus half way across the spiral canal, and winding around the modiolus terminates near the apex in a hook-like or *Hamular process*. Its deficiency in the last half-turn of the cochlea forms the *Helicotrema*, a space in which the *scalæ vestibuli* and *tympani* unite. It consists of two laminae,<sup>1, 2</sup> between which pass the filaments of the cochlear nerve.<sup>10</sup> From its free edge the structures composing the membranous cochlea pass to their attachment on the opposite wall of the cavity.

*Spiral Canal*,—is the space between the modiolus and the outer wall of the cochlea. It makes  $2\frac{1}{2}$  turns,—from left to right in the right ear, from right to left in the left ear; and terminates in the *Cupola*, a cul-de-sac at the apex of the cochlea. It is divided, by the osseous lamina spiralis and the membranous cochlea, into 2 *Scalæ*,—the *Scala Vestibuli*<sup>6</sup> and the *Scala Tympani*.<sup>7</sup> [Fig. 37.]

[A third scala is described by many authorities, the *Scala Media*,<sup>8</sup> including the space contained by the membranous cochlea. See page 92.]

**Describe the Scala Vestibuli.** It is the portion of the spiral canal lying above the lamina spiralis and the membranous cochlea; communi-

cates with the vestibule below, and with the scala tympani above, at the *Helicotrema*. It is filled with perilymph.

**What is the Scala Tympani?** It is the portion of the spiral canal lying below the lamina spiralis and the membranous cochlea, communicates with the aqueductus cochleæ (see below), and with the scala vestibuli at the *Helicotrema*. It terminates inferiorly at the fenestra rotunda, and is filled with perilymph.

**What is meant by the Helicotrema?** It is a space at the apex of the cochlea, formed by the deficiency of the lamina spiralis in the last half turn of the same. In this space the two scalæ are believed to open, thereby communicating with each other.

**What is the Aqueductus Cochleæ?** A small canal which begins by a small orifice in the lower wall of the scala tympani, and runs in the inner wall of the jugular fossa, ending at the edge between the inferior and inner surfaces of the petrous portion of the temporal bone. It transmits a vein from the cochlea to the jugular vein.

**What Parts are comprised in the Membranous Labyrinth?** It consists of two membranous sacs, the *Utricule*<sup>1</sup> and *Sacculæ*,<sup>2</sup> which lie in the vestibule, together with the *Membranous Semicircular Canals*,<sup>6</sup> and the *Membranous Cochlea*.<sup>3,5</sup> The utricle and sacculæ communicate with each other indirectly by a small canal contained in the aqueductus vestibuli. The sacculæ communicates with the membranous cochlea by the *canalis reuniens*,<sup>4</sup> and the membranous semicircular canals open into the utricle; so that the membranous labyrinth presents an uninterrupted channel for the endolymph which it contains

FIG. 36.



**What is the Utricule?** It is a flattened, elliptical membranous sac, fastened to the inner wall of the vestibule in the fovea semi-elliptica. It is filled with endolymph, nearly surrounded by perilymph, and communicates with the sacculæ through the small tube in the aqueductus vestibuli. The membranous semicircular canals open into it by 5 orifices. The wall of the utricle has attached to it the—

*Otoliths, or Ear-stones*,—a powder, consisting of crystals of carbonate of calcium,  $\frac{1}{30000}$  to  $\frac{1}{30000}$  inch in diameter, held together by a mucoid substance.

*Macula Acoustica*,—See below, under *Sacculæ*.



**Describe the Membranous Semicircular Canals.** They are 3 canals, having the same shape as the osseous ones in which they are contained, being fastened thereto by their convex curves, and elsewhere surrounded by perilymph, except at the ampullæ, where they fill the osseous canals. They open into the utricle by 5 orifices.

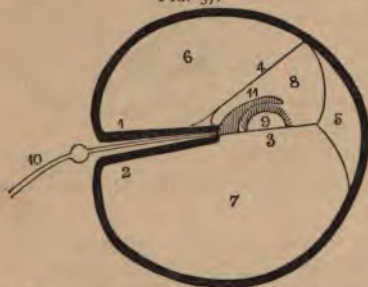
**What is the Sacculæ?** It is a flask-shaped, membranous sac, about  $\frac{1}{15}$  inch in diameter, attached at one point to the utricle, and also to the fovea hemispherica of the vestibule, being elsewhere surrounded by perilymph, and containing endolymph. It communicates with the utricle through the small canal in the aqueductus vestibuli, and also with the membranous cochlea by its neck, the—

*Canalis Reuniens*,—about  $\frac{1}{35}$  inch long and  $\frac{1}{120}$  inch in diameter, is V-shaped, its arms opening respectively into the sacculæ and the vestibular end of the membranous cochlea.

*Macula Acoustica*,—is a dense, circular point,  $\frac{1}{12}$  inch in diameter, on the wall of both the utricle and the sacculæ, formed by a thickening of the connective tissue where the fibres of the vestibular nerve enter it.

**Describe the Membranous Cochlea.** This portion of the membranous labyrinth, also called the *Ductus Cochlearis*, commences in the lower end of the cochlea and ends at its summit in a closed extremity. It is attached on one side to the lamina spiralis, on the other side to the outer wall of the osseous cochlea.

FIG. 37.



It is formed by the *Membrana basilaris*<sup>3</sup> below, the *Membrane of Reissner*<sup>4</sup> on one side, and the periosteum of the cochlear wall on the outer side, its cross-section being of a triangular form. It is filled with endolymph, and contains the *Organ of Corti*<sup>9</sup> covered by the *Membrana tectoria*.<sup>11</sup> The—

*Limbus Laminae Spiralis*,—is the soft structure on the edge of the lamina spiralis, and lies in the membranous cochlea. It has two lips,—an upper, or *labium vestibulare*, a lower, or *labium tympanicum*, with a furrow between them, called the *sulcus spiralis internus*.

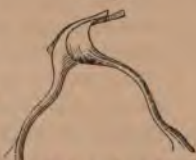*Membrane of Reissner*,<sup>4</sup>—extends from the edge of the lamina spiralis to the outer cochlear wall, forming the vestibular wall of the membranous cochlea. Its outer insertion is the *angulus vestibularis*.

*Membrana Basilaris*,<sup>3</sup>—is the tympanic wall of the membranous cochlea, extending from the labium tympanicum of the lamina spiralis to the outer cochlear wall, where its insertion is called the *Ligamentum spirale*,<sup>5</sup> or *Muscle of Todd and Bowman*. On it rests the *Organ of Corti*,<sup>9</sup> covered by the—

*Membrana Tectoria*,<sup>11</sup>—extends parallel to the membrana basilaris from the labium vestibulare to the outer cochlear wall, where, according to some authorities, it is inserted, according to others it is free and rests directly on the organ of Corti, perhaps to act as a damper to its vibrations.

FIG. 38.

**Describe the Organ of Corti.** It is a peculiar arrangement of cartilaginous rods and epithelial hair cells, which is supposed to constitute the organ of hearing. It lies on the membrana basilaris and is covered by the membrana tectoria. The—



*Rods of Corti*,—are arranged in two rows, resting, by their pedestals, on the membrana basilaris, and uniting with each other by their heads, so as to form an arched tunnel all along the membrane. Number of rods in inner row about 6000, in outer row 4500. Average diameter of the rods, from  $\frac{1}{25000}$  to  $\frac{1}{35000}$  inch.

*Head-plates*,—are attached to the heads of the inner rods, for the reception of the rods of the opposite row.

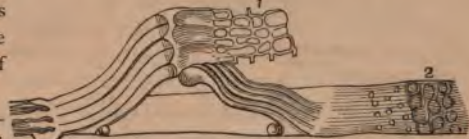*Lamina Reticularis*,<sup>1</sup>—a perforated delicate membrane, which extends from the articulations of the rods outwards to the external wall of the cochlea.

FIG. 39.

*Auditory Cells*,<sup>2</sup>—

are epithelial structures covering the inner surfaces of the walls and the floor of the membranous cochlea. Those which cover the inner rods by a single row number about 3300, are nucleated, covered with tufts of cilia, and called the *inner hair-cells*. On the outer rods are 3 or 4 rows of similar cells, numbering about 18,000, and named the *outer hair-cells*.

*Rings and Phalanges*,<sup>1</sup>—are very minute structures which connect the ciliae of the hair-cells together, and form the lamina reticularis. (See above.)



**Describe the Origin, Course and Distribution of the Auditory Nerve.** The 8th Cranial Nerve, or Portia Mollis of the 7th pair, arises by two roots from the medulla oblongata, one from the floor of the 4th ventricle, the other from a nucleus in the processus e cerebello ad medullam. It winds around the restiform body, from which it receives fibres, and emerges at the lower border of the pons, in company with the facial nerve. The two nerves pass into the internal auditory canal, at the bottom of which the auditory nerve divides into two branches, the vestibular and cochlear nerves. The—

*Vestibular Nerve*,—has a ganglionic swelling on it in the internal auditory canal, and then divides into 3 branches, which pass through the maculæ cribosæ, and are distributed to the utricle, saccule, and the ampullæ of the semicircular canals.

*Cochlear Nerve*,—gives off a small branch to the wall between the utricle and saccule, and then divides into numerous filaments which pass through the small canals in the modiolus, to form a plexus between the two plates of the lamina spiralis, from which filaments pass through the lower edge of the lamina to terminate in the spindle-shaped cells of the Organ of Corti.

*Intumescencia Ganglioniformis Scarpa*,—is the ganglionic swelling on the vestibular nerve in the internal auditory canal.

*Ganglion Spirale*,—is a ganglion found on each filament of the cochlear nerve, just as it enters between the plates of the lamina spiralis.

**What Arteries supply the Labyrinth?** The—

*Internal Auditory Artery*,—br. of the Basilar (from the Vertebral), which accompanies the auditory nerve into the internal auditory canal, where it divides into vestibular and cochlear branches.

*Stylo-mastoid Artery*,—br. of the Posterior Auricular (from the External Carotid), sends some small branches to the internal ear.

**Describe the Internal Auditory Canal.** It begins by a large orifice on the posterior surface of the petrous portion of the temporal bone, and runs outwards for  $\frac{1}{2}$  inch, to end in a blind fossa, the floor of which is perforated by fine foramina, for the passage of the filaments of the nerve to the labyrinth. The—

*Tractus Spiralis Forminosus*,—is a spiral-shaped depression containing a number of the above foramina, and lies opposite the base of the cochlea.

**HERNIA.**

**What is a Hernia?** A protrusion of any viscus from its natural cavity. The term, when unqualified as to the viscus, is understood to mean a protrusion of the intestines or mesentery, or both, from the abdominal cavity.

**Name the Herniæ of most importance anatomically.**

*Oblique Inguinal Hernia*,—in which the protrusion follows the spermatic cord through the inguinal canal; passing to the outer side of the epigastric artery, and through both the internal and external abdominal rings.

*Direct Inguinal Hernia*,—occurs at Hesselbach's triangle, escaping to the inner side of the epigastric artery, and through the external abdominal ring.

*Femoral Hernia*,—in which the protrusion descends through the femoral or crural canal.

**INGUINAL HERNIA.**

**Where is the Inguinal Canal?** It is a passage in the abdominal wall, parallel to Poupart's ligament,<sup>b</sup> and just above it. It commences at the internal abdominal ring and ends at the external abdominal ring, being about 1½ inch in length. It serves for the passage of the spermatic cord in the male, and the round ligament of the uterus in the female; and is directed downwards and inwards. The—

*Internal Abdominal Ring*,—is an oval opening in the transversalis fascia, formed by the prolongation of this fascia around the cord, as the infundibuliform fascia. It lies ½ inch above Poupart's ligament and midway between the anterior superior spine of the ilium and the spine of the pubes. It is bounded above and externally by the arched fibres of the transversalis muscle; below and internally by the epigastric vessels.

*External Abdominal Ring*,<sup>e</sup>—is a triangular opening in the aponeurosis of the external oblique muscle,<sup>a</sup> situated just above and external to the crest of the pubes. It is about 1 inch long, and ½

FIG. 40.



inch wide, and is bounded laterally by its own margins, called the *Internal and External Pillars* of the ring. From these margins is given off the *Intercolumnar fascia*, around the cord and testis.

**What are the Boundaries of the Inguinal Canal ?**

*Anteriorly*,—the Skin, Superficial fascia, External oblique muscle, and the Internal oblique for its outer one-third.

*Posteriorly*,—the Conjoined tendon, Transversalis fascia, Triangular ligament, Sub-peritoneal tissue, and Peritoneum.

*Above*,—the arched fibres of the Internal oblique and Transversalis muscles.

*Below*,—Poupart's ligament, and the Transversalis fascia.

**What is Poupart's Ligament?**<sup>b</sup> The Crural Arch or Poupart's Ligament is that portion of the aponeurosis of the external oblique muscle which extends from the anterior superior spine of the ilium *c* to the spine of the pubes.<sup>d</sup> Its lower portion forms the external pillar of the external abdominal ring,<sup>e</sup> and its reflection along the pectineal line is called *Gimbernal's Ligament*. Other fibres, reflected behind the internal pillar of the ring, upwards to the linea alba, are termed the *Triangular Ligament*.

**What is the relation of the Epigastric Artery to the Internal Abdominal Ring?** The Epigastric artery lies between the transversalis fascia and the peritoneum, passing obliquely upwards and inwards along the lower and inner margins of the internal ring.

**What is the Cremasteric Fascia?** It consists of a series of muscular loops, united by areolar tissue, and forming a thin covering over the spermatic cord. The muscular fibres (Cremaster muscle) are supposed to have been originally part of the Internal oblique muscle, but carried down by the testicle in its descent to the scrotum. It does not exist in the female.

**Name the Coverings of Inguinal Hernia.** In the oblique form of Inguinal Hernia the coverings are—

1. *Skin*.
2. *Superficial fascia*,—2 layers.
3. *Intercolumnar fascia*,—from the external abdominal ring.
4. *Cremasteric fascia*,—from the inguinal canal.
5. *Infundibuliform process* of the transversalis fascia,—from the internal abdominal ring.
6. *Peritoneum*,—the proper hernial sac.

In the direct form of Inguinal Hernia, the coverings are precisely the same, except that the *Conjoined tendon* is substituted for the Cremasteric fascia, and the *Transversalis fascia* for its Infundibuliform process.

A 7th covering is sometimes enumerated, viz., the sub-serous areolar tissue, which would come before the peritoneum in the above list. It is not sufficiently dense to make an appreciable covering.

## FEMORAL HERNIA.

**Where and What is the Femoral Canal?** The Femoral or Crural Canal lies beneath Poupart's ligament, close to the inner side of the femoral vein; and extends from the *femoral ring* to the *saphenous opening* in the fascia lata of the thigh. It is a narrow interval between the femoral vein and the inner wall of the *crural sheath* or sheath of the vessels. The canal is  $\frac{1}{4}$  to  $\frac{1}{2}$  inch in length; is closed above by the *septum crurale*, below by the *cribriform fascia*; and contains only some loose areolar tissue and a few lymphatic vessels. The—

*Femoral or Crural Ring*,—is an oval-shaped opening, about  $\frac{1}{2}$  inch diameter (larger in the female), situated below the internal abdominal ring and Poupart's ligament, and between the inner side of the femoral vein and the margin of Gimbernat's ligament. It is closed by the *septum crurale* and a small lymphatic gland.

*Saphenous Opening*,—(k, Fig. 40) is an oval-shaped structure,  $1\frac{1}{2}$  inch long,  $\frac{1}{2}$  inch wide, situated below the inner third of Poupart's ligament, and formed by a reflection inwards of the fascia lata around the end of the internal saphenous vein. Its outer margin curves over to the spine of the pubes, and is named the *falciform process* (l, Fig. 40), or *ligament of Burns*, its pubic end being often called the *ligament of Hey*. The inner margin curves upward behind the saphenous vein and under the outer margin, and is blended with the pubic portion of the fascia lata over the pectineus muscle. The opening is covered by the *cribriform fascia*.

**What are the Boundaries of the Femoral Canal?**

*Anteriorly*,—Poupart's ligament, Transversalis fascia, and the Falciform process of the fascia lata.

*Posteriorly*,—Iliac fascia, and Pubic portion of the fascia lata.

*Externally*,—the Septum covering the femoral vein.

*Internally*,—Transversalis fascia, Iliac fascia, Gimbernat's ligament, and the deep Crural arch.

**Name the Structures in relation with the Femoral Ring.**

*Spermatic Cord*,—in the male, lies directly above its anterior margin, replaced by the round ligament in the female.

*Femoral Vein*,—lies next on its outer side.

*Epigastric Artery*,—crosses its upper and outer angle.

*Obturator Artery*,—when arising from a common trunk with the epigastric, as it does once in  $3\frac{1}{2}$  subjects, may lie close along its internal and superior margins.

**What is the Septum Crurale?** A layer of condensed cellular tissue, supporting a lymphatic gland, and perforated for the passage of lymphatic vessels. It lies across the femoral ring, and forms one of the coverings to any hernia escaping thereby. It is sometimes named the *fascia of Cloquet*, or *fascia of Cooper*.

**Describe the Crural Sheath.** It is the sheath which invests the femoral vessels below Poupart's ligament, and is formed by a prolongation of the transversalis fascia anteriorly, and the iliac fascia posteriorly. It is divided by two septa into 3 compartments, the exterior of which contains the *femoral artery*, the middle one the *femoral vein*, while the one most internal is the *femoral canal*. The sheath is perforated anteriorly by the genito-crural nerve, internally by the internal saphenous vein, and forms one of the coverings of a femoral hernia.

**What is the Deep Crural Arch?** It is the lower thickened border of the transversalis fascia, which arches across the front of the crural sheath, and is intimately connected therewith. It seems to be attached externally to the centre of Poupart's ligament; internally it is inserted into the pectineal line behind the conjoined tendon.

**Name the Coverings of Femoral Hernia.** From without inwards its coverings are the—

1. *Skin*.
2. *Superficial fascia*,—2 layers.
3. *Cribriiform fascia*,—from the saphenous opening.
4. *Crural sheath*,—from the transversalis fascia.
5. *Septum crurale*,—from the femoral ring.
6. *Peritoneum*,—the proper hernial sac.

## THE PERINEUM.

**What is the Perineum?** It is a triangular space comprising the structures which close the pelvic outlet anterior to a line drawn between the tuberosities of the ischia. Posteriorly to this line is the *Ischio-rectal fossa*. The Perineum is bounded laterally by the rami of the pubes and ischia, anteriorly by the symphysis pubis, and posteriorly by the line above mentioned, which averages about  $2\frac{3}{4}$  inches in length.

[For the Muscles of the Perineum see COMPEND OF ANATOMY, p. 83.]

## THE MALE PERINEUM.

**What Fasciæ are met with in the Perineum?** The

*Superficial Layer of the Superficial Fascia*,—is thick, loaded with fat, and continuous with the subcutaneous fascia of the thighs.

*Deep Layer of the Superficial Fascia*,—is thin but strong, continuous in front with the dartos of the scrotum, attached on each side to the rami of the pubes and ischium; posteriorly it joins the deep perineal fascia under the transversus perinei muscle. It sends inwards a vertical septum which is incomplete in front. [This fascia is called by Professor W. H. Pancoast the "anterior leaflet of the triangular ligament."]

*Anterior Layer of the Deep Perineal Fascia*,—is triangular in shape, and extends from the pubic arch and the sub-pubic ligament, laterally to the rami of the pubes and ischia, and posteriorly to the central tendinous portion of the perineum, where it becomes blended with the deep layer of the superficial fascia. It embraces the anterior part of the membranous portion of the urethra. [Called by Prof. Pancoast, the "middle leaflet of the triangular ligament."]

*Posterior Layer of the Deep Perineal Fascia*,—has the same attachments as the anterior layer above described, but in its course it embraces the posterior part of the membranous portion of the urethra, and is in connection with the apex of the prostate gland. [Called by Prof. Pancoast, the "posterior leaflet of the triangular ligament."]

*Obturator Fascia*,—is the part of the pelvic fascia which covers the obturator internus muscle, and is continued on to the levator ani muscle as the *Ischio-rectal* or *Anal fascia*.

*Recto-vesical Fascia*,—is the portion of the pelvic fascia which invests the internal surface of the levator ani muscle, and the prostate gland, bladder, rectum, and vesiculæ seminales.

**What is the Triangular Ligament of the Urethra?** According to some authorities it is the anterior layer of the deep perineal fascia; according to others it includes the posterior layer also. Professor W. H. Pancoast includes in the term "*triangular ligament*" all three layers which are united at the central tendinous portion of the perineum, including, therefore, the deep layer of the superficial perineal fascia.

**Name the Structures which lie between the layers of the Deep Perineal Fascia.** In this space, which by some writers is termed the Cavity of the Triangular Ligament, are the—

*Membranous Portion of the Urethra.*



<i>Compressor Urethrae Muscle.</i>	<i>Artery of the Bulb.</i>
<i>Pudic Vessels and Nerve.</i>	<i>Nerve of the Bulb.</i>
<i>Cowper's Glands and Ducts.</i>	<i>Plexus of Veins.</i>

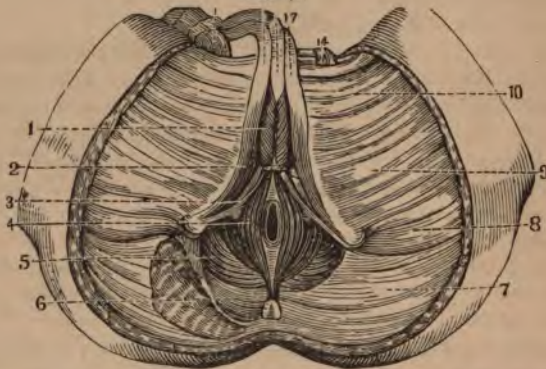
What Structures lie behind the Posterior Layer of the Deep Perineal Fascia? They are the—

<i>Bladder.</i>	<i>Rectum.</i>
<i>Prostate Gland.</i>	<i>Levator ani Muscle.</i>
<i>Ischio-rectal, or Anal Fascia.</i>	

Enumerate the Structures situated between the Anterior Layer of the Deep Perineal Fascia and the Deep Layer of the Superficial Perineal Fascia. They are as follows,—

<i>Crura of the Penis.</i>	<i>Erector Penis Muscle.<sup>2</sup></i>
<i>Corpus Spongiosum.</i>	<i>Transversus Perinei Muscle.<sup>3</sup></i>
<i>Bulb of the Urethra.</i>	<i>Transversus Perinei Artery.</i>
<i>Accelerator Urinae Muscle.<sup>1</sup></i>	<i>Superficial Perineal Vessels.</i>

FIG. 41.



Enumerate the Structures which are divided in the lateral operation of Lithotomy. If the knife is inserted  $1\frac{1}{4}$  inch above the verge of the anus, and carried to a point  $\frac{3}{4}$  inch below that orifice, and about half-way outwards to the tuber ischii (*Gross*), it will divide the—

*Skin and Superficial Fascia (1st Layer).*  
*Inferior Hemorrhoidal Vessels and Nerves.*  
*Deep Layer of the Superficial Fascia.*  
*Superficial Perineal Vessels and Nerves.*  
*Accelerator Urinae Muscle<sup>1</sup> (posterior fibres).*

*Transversus Perinei Muscle<sup>3</sup> and Artery.*  
*Anterior Layer of the Deep Perineal Fascia.*  
*Compressor Urethrae Muscle* (a few fibres).  
*Levator Ani Muscle<sup>5</sup>* (anterior fibres).  
*Membranous and Prostatic Portions of the Urethra.*  
*Posterior Layer of the Deep Perineal Fascia.*  
*Prostate Gland* (in part only).  
*Neck of the Bladder.*

**What Parts are to be avoided in the Lateral operation of Lithotomy?** They are as follows, viz: The—

*Bulb and its Artery*,—in front.

*Rectum*,—inwardly and posteriorly.

*Pudic Artery*,—outwardly.

*Prostate Gland and Veins*,—by not carrying the deep incision too far backwards, the entire division of the left lobe of this gland will be avoided.

#### THE FEMALE PERINEUM.

**What especial Function does the Female Perineum perform?**

That of supporting the posterior wall of the vagina, and thereby aiding materially in the support of the whole vagina, uterus and bladder. The—

*Perineal Body*,—is the pyramidal-shaped prolongation of the female perineum upwards, between the vagina and rectum.

**Enumerate the chief points of Difference between the Female Perineum and that of the Male.** The—

*Orifice of the Vulva*,—including the vaginal orifice, perforates the female perineum, its posterior commissure approaching the anal margin within about an inch.

*Superficial Fascia*,—is incomplete, by reason of its perforation by the orifice of the vulva.

*Deep Perineal Fascia*,—being also perforated by the vagina, is less apparent than in the male, though presenting two layers, with the urethra perforating them.

*Muscles*,—the Sphincter vaginæ takes the place, in the female, of the Accelerator urinæ of the male.



CLASSIFIED CATALOGUE  
OF THE PUBLICATIONS OF  
**P. BLAKISTON, SON & CO.,**  
No. 1012 Walnut St., Philadelphia.

Any book sent, postpaid, upon receipt of price  
Correspondence invited.

Full Descriptive Catalogues of these books,  
also a Classified list of ALL Medical Publica-  
tions, English and American, to be had in the  
American market, mailed free upon application.

ACTION OF MEDICINES.

- Brunton**, The Action of Medicines. Pt. 1. Circulation. *[In Press.]*  
**Headland**, on the Action of Medicines. 9th Ed. \$3.00  
**Ott**, The Action of Medicines. 22 Illustrations. \$2.00  
**Rutherford**, Physiological Action of Drugs on the Secretion of Bile. 100 Illustrations. \$3.00

ANATOMY.

*(See also Osteology, and Atlases.)*

- Quiz-Compend**, Visceral Anatomy. \$1.00  
**Braune**, Topographical Anatomy. Photo-lithographic plates. 4to. \$8.00  
**Heath**, Practical Anatomy. Fifth London Edition. Nearly 300 Illustrations. \$5.00  
**Holden**, Anatomy and Dissections of the Human Body. Fourth Edition. 170 Illustrations. \$5.50  
———, Landmarks. 3d Edition. 1.00  
**Handy**, Anatomy. Illustrated. \$3.00  
**Jones**, Sieveking & Payne. Pathological Anatomy. Illustrated. \$5.50  
**Morris**, Anatomy of the Joints. Colored Illus. \$5.50  
**Quiz-Compend**, Anatomy. By Potter. 63 Illustrations. \$1.00  
**Virchow**, Post-mortem Examinations. Second Edition. Illustrated. \$1.25  
**Wilkes & Moxon**, Pathological Anat. 2d Ed. \$6.00  
**Wilson's Anatomy**. 10th London Edition. \$6.00

ASTHMA

- Berkart**, Pathology and Treatment of. \$2.50  
**Phorowgood**, Nature and Treatment of. \$1.50

ATLASES, PLATES AND DIAGRAMS.

- Bentley & Trimens**, Medicinal Plants. Full Botanical Descriptions and Colored Plates of all Plants Employed in Medicine, their Properties and Uses. 4vols. 4to, half morocco. \$30.00

P. BLAKISTON'S PUBLICATIONS.

- Bock, Atlas of Anatomy, 38 Col. plates. Roan \$15.00  
 Flower, Diagrams of the Nerves of the Human Body.  
 7 Double-page Plates, and Letter Press. 4to. \$3.50  
 Frieriepl, Anat. Atlas, 75 Pl. Plain, \$5.00; Col. \$10.00  
 Godlee, Atlas of Human Anatomy. 48 Colored  
 Plates. Over 200 Figures. 4to Volume of Plates.  
 and 8vo Volume of Text. \$20.00  
 Heath, Operative Surgery. Col. Plates. \$14.00  
 Hutchinson, Illustrations of Clinical Surgery, Con-  
 sisting of Plates and wood-cuts. 4to. \$25.00  
 Parts 11, 12, 13, 14, 15, now ready, each \$2.50  
 Jones, Atlas of Diseases of the Membrana Tympani.  
 62 Colored Figures. \$4.00  
 Liebreich, Atlas of Ophthalmoscopy. 12 Chromo-  
 lithographic Plates, 59 Figures. 2d Ed. \$12.00  
 Marshall, Diagrams of the Human Body." 11 Life-  
 sized Col. Plates. Sheets, \$50.00; Mounted, \$80.00  
 Schultze, Obstetrical Plates. Life Size. 20 in the  
 Set. Sheets, \$15.00; Mounted, \$25.00

BRAIN AND INSANITY.

- Bucknill & Tuke, Psychological Medicine. Fourth  
 Edition. Illustrated. \$3.00  
 Sankey, Mental Diseases. \$3.00  
 Sheppard, On Madness. \$2.25  
 Wood, Brainwork and Overwork. Paper 30, Cloth. 50

CANCER.

- Collis, Diagnosis and Treatment of. Col. Plates. \$3.00  
 Cripps, Cancer of the Rectum. Illustrated. \$2.40  
 Marsden, Treatment of. Second Edition. Illus. \$3.00  
 Purcell, On Cancer, Its Allies and Other Tumors,  
 with Treatment. Illustrated. \$3.75

CHEMISTRY.

- Allen, Commercial Organic Analysis. 2 Vols. \$8.50  
 Bloxam, Chemistry, Organic and Inorganic. 295 Il-  
 lustrations. Fourth London Edition. \$4.00  
 ———, Laboratory Teaching. 89 Illus. \$1.75  
 Bernay, Notes for Chemistry Students. 6th Ed. \$1.25  
 Frankland, How to Teach Chemistry. Illus. \$1.25  
 ———, Water Analysis. Illustrated. \$1.00  
 Quiz-Compend. Chemistry. \$1.00  
 Kollmyer, Chemia Coartata; Key to Chemistry. \$2.25  
 Muter, Medical and Pharmaceutical Chemistry. \$5.00  
 Reese, Syllabus of Medical Chemistry. \$1.00  
 Sutton, Volumetric Analysis. Illus. 4th Ed. \$5.00  
 Tidy, Modern Chemistry; Organic and Inorganic. \$5.00  
 Vacher, Primer of Chemistry. .50  
 Muter, Practical and Analytical Chemistry, \$2.50

CHILDREN, DISEASES OF.

- Lucy, Diseases of Children. Second Edition. Just  
 ready. Cloth, \$5.00; sheep, \$6.00

CLASSIFIED LIST,

- Dillinger**, Diseases of Women and Children. \$1.70  
**Ellis**, Diseases of Children. 4th Ed. \$3.50  
 ———, What Every Mother Should Know. .75  
**Hale**, The Management of Children. .50  
**Hillier**, The Diseases of Children. \$2.00  
**Meigs & Pepper**, Diseases of Children. Seventh Edition. Cloth, \$6.00; sheep, \$7.00  
**Smith**, Diseases of the Lungs in Children. \$2.50  
**Tanner**, Diseases of Infancy and Childhood. \$3.00

CLIMATOLOGY AND HEALTH RESORTS.

- Madden**, Health Resorts for Chronic Diseases. \$2.50  
**Wilson**, The Ocean as a Health Resort. \$2.50

DYSPEPSIA AND INDIGESTION.

- Edwards**, Dyspepsia and How to Avoid It. .75  
 ———, Constipation. .75  
**Gill**, Indigestion, a New Method of Treatment. \$1.25  
**Habershon**, The Varieties of Dyspepsia and Their Treatment. Paper, 75 cents; Cloth, \$1.25  
**Leared**, Imperfect Digestion and Its Treatment. \$2.00

DEFORMITIES.

- Adams**, Club-Foot, Causes and Treatment. \$5.00  
**Brodhurst**, Anchylosis. Fourth Edition. \$2.00  
**Coles**, Deformities of the Mouth, and Their Treatment. Third Edition. 179 Illustrations. \$4.50  
**Mac Ewen**, Osteotomy. Illustrated. \$3.00

DENTISTRY.

- Coles**, Deformities of the Mouth, with Treatment. Third Edition. 179 Illustrations. \$4.50  
 ———, Dental Mechanics. 140 Illustrations. \$2.00  
 ———, Dental Student's Note-Book. New Ed. \$1.00  
**Flagg**, Plastics and Plastic Filling. Illus. \$3.00  
**Heath**, Diseases of the Jaws. 150 Illus. \$4.25  
**Hunter**, Mechanical Dentistry. 100 Illus. \$2.25  
**Harris**, Principles and Practice of Dentistry. Tenth Edition. 400 Illus. Cloth, \$6.50; sheep, \$7.50  
 ———, Dental and Medical Dictionary. Fourth Edition. Cloth, \$6.50; sheep, \$7.50  
**Leber & Rottenstein**, Dental Caries. \$1.25  
**Richardson**, Mechanical Dentistry. Third Edition. 185 Illustrations. Cloth, \$4.00; sheep, \$4.75  
**Sewell**, Dental Anatomy and Surgery. Illus. Paper, 75 cents; Cloth, \$1.25  
**Stocken**, Dental Materia Medica and Therapeutics. Third Edition. \$2.25  
**Tomes, Z.**, Dental Surgery. Second Edition. \$5.00  
**Tomes, C. S.**, Dental Anatomy. Second Edition. 101 Illustrations. \$4.25  
**Taft**, Operative Dentistry. 4th Ed. \$4.15  
**Wedl**, Dental Pathology. Cloth, \$3.50; sheep, \$4.50  
**White**, The Mouth and Teeth. Illustrated. .50

DICTIONARIES.

- Cleveland**, Pocket Medical Lexicon. Twenty-ninth Edition. Cloth, .75; tucks, \$1.00

P. BLAKISTON'S PUBLICATIONS.

- Cooper, Surgical Dictionary. Two Volumes. \$12.00  
 Harris, Dictionary of Medicine and Dentistry.  
 Fourth Edition. Cloth, \$6.50; sheep, \$7.50  
 Longley, Medical Lexicon. Cloth, \$1.00; tucks, \$1.25  
 Mayne, Medical Vocabulary. An Explanation of all  
 Synonyms, Names and Terms. Fifth Edition. \$4.00

EAR, DISEASES OF.

- Burnett, Hearing and How to Keep It. Illus. .50  
 Dalby, Diseases and Injuries of the Ear. Illus. \$1.50  
 Jones, H. M., Aural Surgery. Illustrated. \$2.75  
 ———, Atlas of Diseases of the Membrana Tym-  
 pani. Colored Plates, 62 Figures. \$6.00.  
 Woakes, Deafness, Giddiness, and Noises in the  
 Head. Second Edition. Illustrated. \$2.50  
 ———, Nasal Catarrh. *In preparation.*

ELECTRICITY.

- Althaus, Medical Electricity. 3d Ed. 146 Ill. \$6.00  
 Reynolds, Civil Uses of Electricity. 2d Ed. \$1.50

EYE, DISEASES OF.

- Carter, Eyesight, Good and Bad. Second Edition.  
 50 Illustrations. \$1.25  
 Daguenet, Manual of Ophthalmoscopy. Illus. \$1.50  
 Fenner, Vision, Its Optical Defects. 74 Illus. \$3.50  
 Gowers, Manual and Atlas of Ophthalmoscopy. 112  
 Illustrations, some colored. Second Edition. \$6.00  
 Harlan, Eyesight and How to Care for It. Illus. .50  
 Hay, Sarcomatous Tumor of the Orbit in a Child.  
 Illustrated. .50  
 Higgins, Hand-book of Ophthalmic Practice. .50  
 Jones, Defects of Sight and Hearing. .50  
 Liebreich, Atlas of Ophthalmoscopy. 59 Colored  
 Figures. Second Edition. 4to. \$13.00  
 Macnamara, Diseases of the Eye. Fourth Edition.  
 Colored Plates and Wood Cuts. \$4.00  
 Morton, On Refraction. \$1.00  
 Walton, Diseases of the Eye. Third Edition. Illus-  
 trated. 1200 pages. \$9.00  
 Wolfe, Diseases of the Eye. Illustrated. \$7.00

FEVERS.

- Allan, Fever Nursing. Illus. .75  
 Stillé, Epidemic Meningitis. \$2.00

HEADACHES.

- Day, Headaches, Their Nature, Causes and Treat-  
 ment. Fourth Edition. Illus. Paper, 75; cloth, \$1.25  
 Liveing, Megrin, or Sick Headache and Allied Dis-  
 orders. Illustrated. \$5.50  
 Wright, Headaches, Their Causes and Cure. .50

HEART.

- Bruen s, Physical Diagnosis. Illustrated. \$2.00  
 Barth & Roger, Auscultation and Percussion. \$1.00

CLASSIFIED LIST,

- Fothergill, Treatment of Diseases of the Heart.  
Formulae and Illustrations. \$3.50  
Hayden, Diseases of the Heart and Aorta. 81 illus-  
trations. 1200 pages. Two Volumes. \$6.00  
Sansom, Physical Diagnosis of Diseases of the  
Heart. Third Edition. Illustrated. \$2.00  
Stokes, Diseases of the Heart and Aorta. \$3.00

HISTOLOGY.

(See also Pathology.)

- Gibbes, Practical Histology and Pathology. \$1.00  
Rutherford, Practical Histology. 3d Ed. *[In Press.]*

HOSPITALS.

- Burdett, Cottage Hospitals. Second Edition. Plans  
and Illustrations. \$4.50  
—, Pay Hospitals and Paying Wards.  
Domville, Hospital Nursing. Second Edition. .75

HYGIENE.

- Bible Hygiene. By a Physician. Pap., .50; Cl., \$1.00  
Bennett, Nutrition in Health and Disease. \$2.50  
Corfield, Sanitary Construction and Arrangement of  
Dwelling Houses. Plans and Illus. 2d Ed. \$1.25  
Frankland, Water Analysis for Sanitary Purposes,  
Illustrated. \$1.00  
Hartshorne, Our Homes, Their Sanitary Arrange-  
ments. Illustrated. Paper, 30 cents; Cloth, .50  
Lincoln, School Hygiene. Paper, 30 cents; Cloth, .50  
Parkes, Complete Practical Hygiene. Fifth Edition.  
Illustrated. \$6.00  
Wilson, G., Hygiene and Sanitary Science. Fourth  
Edition. Illustrated. \$2.75  
—, How to Live. A Guide to Health and  
Healthy Homes. 314 pages. Paper, .75; Cloth, \$1.00  
—, *Y.*, Drainage for Health. Easy Lessons in  
Sanitary Science. Illustrated. \$1.00  
—, Naval Hygiene, Human Health, and the  
Means for Preventing Disease. Illustrated. \$3.00  
Teale, Dangers to Health. 3d Ed. Illus. \$3.50

JOURNALS.

- The Medical Register. A Journal of Medical  
Literature. Monthly. Per Annum, \$1.00  
The Ophthalmic Review. Monthly. Per Annum,  
\$3.00

KIDNEYS AND LIVER.

- Black, Bright's Disease of the Kidneys. 20 Illus. \$1.50  
Edwards, How Persons Afflicted with Bright's Dis-  
ease Ought to Live. .75  
Greenhow, Addison's Disease. Numerous Cases  
and Colored Illustrations \$3.00  
Harley, Diseases of the Liver. Illustrated.  
Cloth, \$5.00; leather, \$6.00  
Tyson, Bright's Disease and Diabetes. Illus. \$3.50

LUNGS AND CHEST, DISEASES OF.

(See also Throat.)

- Bennett, Consumption, Treated by Hygiene, Climate  
and Medicine. Third Edition. \$2.50  
Barth & Roger, Auscultation and Percussion. \$1.00



P. BLAKISTON'S PUBLICATIONS.

Bruen's, Physical Diagnosis. Illustrated.	\$2.00
Dobell, Loss of Weight, Blood Spitting, etc.	\$4.00
—, Winter Cough, Catarrh, Bronchitis, Asthma, etc. Third Edition. Illustrated.	\$3.50
Greenhow, Bronchitis.	\$1.50
Waters, Diseases of the Chest. 2d Ed.	\$4.00

MANUALS FOR STUDENTS.

Mendenhall, Student's Vade Mecum. Illus.	\$2.00
Athill, Diseases of Women. Fifth Ed. Illus.	\$1.25
Bernay, Notes for Chemical Students.	\$1.25
Carter, Practical Medicine.	\$3.00
Charteris, Practice of Medicine. Illustrated.	\$1.25
Clay, Obstetrics. Illustrated.	\$2.00
Dalby, On the Ear. Illustrated.	\$1.50
Penwick, Outlines of Practice. Illustrations and Formulae. Paper, 75 cents; Cloth,	\$1.25
Gallabin, Diseases of Women. 63 Illus.	\$1.25
Heath, Minor Surgery. Sixth Edition. Illus.	\$2.00
—, Surgical Diagnosis. Paper, 75 cents;	\$1.25
Marshall & Smith, Analysis of the Urine.	\$1.00
Mears, Practical Surgery. Illustrated.	\$2.00
Roberts, Practice of Midwifery. 95 Illus.	\$1.25
Sewill, Dental Anatomy and Surgery. Illus.	\$1.25
Smith, Practical Gynecology. Illustrated.	\$1.25
Swain, Surgical Emergencies. 82 Illustrations.	\$2.00
Tyson, Practical Examination of the Urine. Third Edition. Illustrated.	\$1.50
Bruen's, Physical Diagnosis. Illustrated.	\$2.00
Quiz-Compend. Send for circular.	

MARRIAGE.

Ryan, The Philosophy of Marriage.	\$1.00
Walker, Intermarriage, Its Effects on Health, Beauty, etc. Illustrated.	\$1.00

MATERIA MEDICA.

(See also *Therapeutics*.)

Biddle, Materia Medica, Ninth Edition.	\$4.00
Royle & Harley, Materia Medica and Therapeutics. 139 Illustrations.	\$5.00
Stocken, Dental Materia Medica and Therapeutics. Third Edition.	\$2.25
Thorowgood, Guide to Materia Medica.	\$2.00
Potter's Compend of Materia Medica.	\$1.00

MEDICAL JURISPRUDENCE AND

TOXICOLOGY.

Ogston, Medical Jurisprudence. Illustrated.	\$6.00
Tanner, Poisons and Their Antidotes. Fourth Ed.	.75
Woodman & Tidy, Medical Jurisprudence and Toxicology. Illustrated. Cloth, \$7.50; sheep, \$8.50	

MICROSCOPY.

Carpenter, The Microscope and Its Revelations. Sixth Edition. 500 Illustrations.	\$5.50
---	--------

CLASSIFIED LIST,

<b>Beale, How to Work with the Microscope.</b> Fifth Edition. 400 Illustrations.	\$7.50
—, <b>The Microscope in Medicine.</b> Fourth Edition. 500 Illustrations.	\$7.50
<b>Marsh, Section Cutting.</b> Illustrated.	
<b>Martin, Microscopic Mounting.</b> 140 Illustrations. Second Edition.	\$2.75
<b>Macdonald, Microscopical Examination of Water.</b> 20 Plates.	\$2.75
<b>Wythe, The Microscopist.</b> Fourth Edition. 252 Illustrations.	Cloth, \$3.00; sheep \$4.00

MISCELLANEOUS.

<b>Beale, Life and Vital Action.</b>	\$5.00
—, <b>Life Theories and Religious Thought.</b> Illustrated.	\$2.00
—, <b>Slight Ailments.</b> 2d Edition, Enlarged and Illustrated.	Paper, 75; Cloth, \$1.25
<b>Bennett, Nutrition in Health and Disease.</b> Third Edition.	\$2.50
<b>Carson, History of the University of Pennsylvania.</b>	\$2.00
<b>Cohen, Inhalation, its Therapeutics and Practice.</b> Illustrated.	\$2.50
<b>Cobbold, Parasites; the Entozoa of Man and Animals.</b> 85 Illustrations.	\$5.00
<b>Edwards, Constipation.</b>	.75
—, <b>On Malaria</b>	.75
<b>Gross, Life of John Hunter.</b> Illustrated.	\$1.50
<b>Hardwicke, Medical Education.</b>	\$3.50
<b>Hood, On Gout and Rheumatism.</b> Second Ed.	\$3.50
<b>Holden, The Sphygmograph.</b> 300 Illustrations.	\$2.00
<b>Hunter, Phototype Portrait of.</b>	.50
<b>Kane, On the Opium, Morphia, Chloral and other Habits.</b> Illustrated.	\$1.50
<b>Kirby, On Phosphorus.</b> New Edition.	\$1.00
<b>Lizars, On Tobacco.</b>	.50
<b>Mathias, Legislative Manual and Rules of Order.</b>	.50
<b>Overman, Practical Mineralogy.</b>	\$1.00
<b>Oldberg, Metric System in Medicine.</b> Formulae.	\$1.25
<b>Pieasse, The Art of Perfumery.</b> 366 Illus.	\$5.50
<b>Pennsylvania Hospital Reports.</b> Each.	\$2.00
<b>Piggot, Copper Mining and Copper Ore.</b>	\$1.00
<b>Smith, On Ringworm and Its Treatment.</b> Illus.	\$1.00
<b>Smythe, Medical Heresies.</b>	\$1.25
<b>Sieveking, Life Assurance.</b> Second Edition.	\$2.00
<b>Transactions of the College of Physicians of Philadelphia.</b> Five Volumes. Each	\$2.50
<b>Turnbull, Anesthesia.</b> Second Edition. Illus.	\$1.50
<b>Virchow, Post-mortem Examinations.</b> Second Edition. Illustrated.	\$1.25
<b>Warner, Medical Case Taking.</b>	\$1.75

NERVOUS DISEASES.

<b>Buzzard, Nervous Diseases.</b>	\$5.00
<b>Flower, Diagrams of the Nerves.</b> 7 Double-page Plates and Letter Press. 4to.	\$3.50

P. BLAKISTON'S PUBLICATIONS.

- Gowers, Diseases of the Spinal Cord. Second Edition. Illustrated. \$1.50  
 Page, Injuries of the Spine, and Nervous Shock. \$4.00  
 Radcliffe, Epilepsy, Pain and Paralysis. Illus. \$1.50

NURSING.

- Allan, Notes on Fever Nursing. Illustrated. .75  
 Cullingworth, Manual of Nursing. \$1.00  
 Domville, Manual for Nurses. Fourth Edition. .75  
 Smith, On the Training of Nurses. Illustrated. \$2.00

OBSTETRICS.

- Cazeaux, Practical Text-book of Midwifery. Seventh Edition. Illustrated. Cloth, \$6.00; sheep, \$7.00  
 Clay, Obstetric Surgery. Illustrated. \$2.00  
 Glisan, Midwifery. 130 Illus. Clo. \$4.00; sheep, \$5.00  
 Meadows, Manual of Midwifery. 145 Illustrations. Revised Edition. \$2.00  
 Rigby and Meadows, Obstetric Memoranda. Fourth Edition. .50  
 Roberts, Practical Midwifery. 95 Illustrations. \$1.25  
 Savage, Surgery of the Female Pelvic Organs. Colored Plates. Second Edition. \$12.00  
 Schultze, Obstetric Diagrams, Life Size. 20 in Set. In Sheets, \$15.00; Mounted, \$25.00

OSTEOLOGY.

- Holden, Human Osteology. Colored and other Illustrations. Sixth Edition. \$6.00  
 Mac Ewen, Osteotomy. 51 Illustrations. \$3.00  
 Macnamara, Diseases of the Bones and Joints. \$4.25  
 Wagstaffe, Human Osteology. 83 Illustrations. \$3.00

PATHOLOGY.

(See also *Histology*.)

- Gibbes, Practical Pathology and Histology. \$1.00  
 Jones, Sieveking & Payne, Pathological Anatomy. Illustrated. \$5.50  
 Paget, Surgical Pathology. Third Edition. Illustrated. Cloth, \$7.00; sheep, \$8.00  
 Rindfleisch, Pathological Histology.  
 Thudichum, Path. of the Urine. 2d Ed. Illus. \$5.00  
 Virchow, Pathology. \$5.00  
 Wedl, Dental Pathology. 105 Illustrations. Cloth, \$3.50; sheep, \$4.50  
 Virchow, Post-mortem Examinations. Illus. \$1.25  
 Wilkes & Moxon, Pathological Anatomy. \$6.00

PHARMACY.

- Beasley, Druggists' General Receipt Book. \$2.25  
 ———, Formulary. \$2.25  
 Bentley & Trimens, Medicinal Plants. Colored Plates and Descriptions of Every Plant Employed in Medicine, Their Properties and Uses. Four Vols., half Morocco. \$90.00  
 Brewing, Distilling, and Wine Manufacture. \$1.75

CLASSIFIED LIST,

Mackenzie, Pharmacopœia of the Throat Hospital. Fourth Edition.	\$1.25
Muter, Pharmaceutical and Medical Chemistry.	\$6.00
Oldberg, The Metric System, Posological Tables and 300 New Prescriptions.	\$1.25
— The Unofficial Pharmacopœia. Over 700 Formulæ.	\$3.50
Piesse, The Manufacture of Perfumery, Cosmetics, Soaps, Tooth Powders, etc. 4th Ed. 366 Ill.	\$5.50
Sweringen, Pharmaceutical Lexicon. Cloth.	\$3.05
Tuson, Veterinary Pharmacopœia, Materia Medica and Therapeutics. Third Edition.	\$2.00

PRACTICE.

Aitken, The Science and Practice of Medicine. Third American Edition. Two Volumes. Cloth.	\$12.00
Beale, Slight Ailments, and their Treatment.	\$1.25
Carter, Elements of Practical Medicine.	\$3.00
Charteris, Students' Hand-book of Practice. II.	\$1.25
Cormack, Clinical Studies. Illus. Two Vols.	\$5.00
Dunglison, Practitioner's Reference Book.	\$3.50
Fenwick, Outlines of Practice. Formulæ and II.	\$1.25
Foster, Clinical Medicine. Illustrated.	\$3.00
Maxson, Practice of Medicine.	\$3.00
Power, Holmes, Anstie & Barnes, Reports on the Progress of Medicine.	\$2.00
Quiz-Compends. Practice, 2 Parts, Each	\$1.00
Roberts, Text-book of the Theory and Practice of Medicine. Third Edition. Cloth, \$5.00; sheep, \$6.00	
Trousseau, Clinical Medicine. Third Edition. Two Volumes. Cloth, \$8.00; sheep, \$10.00. Ditto. Five Volumes. Sydenham Edition.	\$15.00
Tanner, Index of Diseases and Their Treatment. Formulæ, etc.	\$1.00
Warner, Student's Guide to Case Taking.	\$1.75
Bruen's, Physical Diagnosis. Illustrated.	\$2.00

PHYSIOLOGY.

Beale, Bioplasm, or the Physiology of Life. II.	\$2.25
—, Protoplasm, or Matter and Life. Col. II.	\$3.00
Fulton, Physiology. Second Edition. Illus.	\$4.00
Kirke, Physiology. 10th London Ed. Illus.	\$5.00
Quiz-Compend. Physiology.	\$1.00
Reese, Analysis of Physiology. Second Edition.	\$1.50
Sanderson, Hand-book of the Physiological Laboratory. 350 Illus.	cloth, \$5.00; sheep \$6.00
— Syllabus of Physiology. Second Ed.	\$1.50
—, Practical Exercises.	\$1.12
Tyson, The Cell Doctrine. Second Ed. Illus.	\$2.00

PRESCRIPTION BOOKS.

Beasley, 3000 Prescriptions, and Index of Diseases and Remedies. Fifth Edition.	\$2.25
Oldberg, The Metric Prescription Book. 300 Formulæ and Posological Tables.	\$1.25
Pereira, Physician's Prescription Book Sixteenth Edition.	Cloth, \$1.00; Tucks, \$1.25
Wythe, Physician's Pocket Dose and Symptom Book. Eleventh Edition.	Cloth, \$1.00; Tucks, \$1.25

P. BLAKISTON'S PUBLICATIONS.

POPULAR MEDICINE.

**American Health Primers:**

- Price, Paper, 30 cents; Cloth, 50 cents.
- I. Hearing and How to Keep It. Chas H. Burnett, M.D. Illustrated.
- II. Long Life and How to Reach It. J. G. Richardson, M.D.
- III. Summer and Its Diseases. Jas. Wilson, M.D.
- IV. Eyesight and How to Care For It. Geo. C. Harlan, M.D. Illustrated.
- V. The Throat and Voice. J. Solis Cohen, M.D. Illustrated.
- VI. The Winter and Its Dangers. Hamilton Osgood, M.D.
- VII. The Mouth and the Teeth. J. W. White, M.D. Illustrated.
- VIII. Brainwork and Overwork. H. C. Wood, M.D.
- IX. Our Homes. Henry Hirtshorne, M.D., Illus.
- X. The Skin in Health and Disease. J. D. Bulkley, M.D. Illustrated.
- XI. Sea Air and Sea Bathing. J. H. Packard, M.D.
- XII. School and Industrial Hygiene. D. L. Lincoln, M.D.

- Carter, Eyesight, Good and Bad. Illustrated. \$1.25
- Chavasse, Training of Children. Pap., 50; Cl., \$1.00
- Ellis, What Every Mother Should Know. .75
- Edwards, How Persons Afflicted with Bright's Disease Ought to Live. .75
- , Constipation Cured without Drugs. .75
- , Dyspepsia and How to Avoid It. .75
- , On Malaria. .75
- Gill, On Indigestion. Second Edition. \$1.25
- Hale, The Management of Children. For Mothers. .75
- Hufeland, The Art of Prolonging Life. \$1.00
- Savory & Moore, Compend of Domestic Medicine and Guide to Medicine Chest. .50
- Tanner, Poisons and Their Antidotes. Fourth Ed. .75
- Thompson, Coughs and Colds. .60
- Wilson, G., How to Live. Paper, .50; Cloth, \$1.00
- Wilson, W. S., Sea Voyages for Health. \$2.50
- Wright, On Headaches, Their Causes and Cure. Ninth Thousand. .50
- Walker, Internmarriage for Health and Beauty. Illustrated. \$1.00

RECTUM.

- Allingham, Diseases of the Rectum. Fourth Edition, Enlarged. Illustrated. Paper, .75; cloth, \$1.25
- Cripps, Cancer of the Rectum, and Treatment. \$2.40

SKIN AND HAIR.

- Anderson, Eczema, Its Treatment, etc., \$2.50
- Bulkley, Aid to the Study of Skin Diseases. Illus. .30
- Cobbold, Parasites and Entozoa. 85 Illus. \$5.00
- Cottle, The Hair in Health and Disease. .75
- Pharmacopœia of London Hospital for Skin Diseases.

CLASSIFIED LIST,

- Fox, Tilbury**, Atlas of Skin Diseases. 72 Quarto Colored Plates. 18 Parts, each \$2.00; or, One Volume, Cloth. 4to. \$20.00  
**Wilson**, Healthy Skin and Hair. Eighth Ed. \$1.00

STIMULANTS AND NARCOTICS.

- Anstie**, Stimulants and Narcotics. \$3.00  
**Kane**, The Opium, Chloral, Morphine and Hashisch Habits. Illustrated. \$1.50  
**Lizars**, On Tobacco, Its Use and Abuse. .50  
**Miller**, On Alcohol, Its Place and Power. .50  
**Sansom**, Chloroform. Its Administration. \$1.50  
**Turnbull**, Artificial Anaesthesia. 2d Ed. Illus. \$1.00

STOMACH.

- Fenwick**, The Stomach and Duodenum. Illus. \$4.25  
 ———, Atrophy of the Stomach. Illustrated. \$3.20  
**Habershon**, Diseases of the Stomach. Third Ed. \$1.25

SPECTROSCOPE.

- Mac Munn**, The Spectroscope in Medicine. Colored and other Illustrations. \$3.00

SURGERY AND SURGICAL DISEASES.

(See also *Deformities, and Osteology*.)

- Aveling**, Influence of Posture on Women In Operations. Illustrated. \$2.00  
**Clarke**, Outlines of Surgery. Second Edition. \$2.00  
**Cooper**, Surgical Dictionary. Two Volumes. \$12.00  
**Druitt**, Surgery. 11th London Edition. 369 Illus. \$5.00  
**Gant**, Practice of Surgery. 2d Ed. Two Vols. 1700 pages. 1000 Illus. Cloth, \$11.00; sheep, \$13.00  
**Heath**, Operative Surgery. Col. Plates. 4to. \$14.00  
 ———, Minor Surgery. Sixth Edition. Formulae and 115 Illustrations. \$2.00  
 ———, Surgical Diagnosis. Paper, .75; \$1.25  
 ———, Injuries and Diseases of the Jaws. Second Edition. 150 Illustrations. \$4.25  
**Holden's Landmarks**, Medical and Surgical. \$1.00  
**Hutchinson**, Illustrations of Clinical Surgery. Cases Illustrated by Colored Plates, Wood Cuts, Photographs, etc. Parts 1-10 bound. Cloth, \$25.00  
 Parts 11, 12, 13 and 14 ready. Each \$2.50  
**Hewson**, Earth as Applied in Surgery. Illus. \$2.50  
**Mears**, Practical Surgery. Illustrated. \$2.00  
**Macnamara**, Diseases of the Bones and Joints. \$4.25  
**Mason**, Surgery of the Face. 100 Illustrations. \$2.25  
**Maunder**, Operative Surgery. \$2.00  
 ———, Surgery of the Arteries. Illustrated. \$1.50  
**Page**, Injuries of the Spine, and Nervous Shock. \$4.00  
**Prince**, Plastic and Orthopaedic Surgery. Illus. \$4.50  
**Swain**, Surgical Emergencies. Illustrated. \$2.00  
**Tomes**, Dental Surgery. Second Ed. 263 Illus. \$5.00  
**Toland**, Practical Surgery. Second Edition. \$4.50

P. BLAKISTON'S PUBLICATIONS.

THROAT.

(See also *Lungs, and Asthma.*)

- Cohen, Throat and Voice. Illus. Paper, 30; Cloth, .50  
 ———, On Inhalation. Illus. Second Edition. \$2.50  
 ———, Croup, Its Relations to Tracheotomy. \$1.00  
 Dobell, Winter Cough, Catarrh, Asthma, Bronchitis,  
 etc. Third Edition. Illustrated. \$3.50  
 Holmes, Vocal Physiology and Hygiene. Illus. \$2.00  
 ———, The Laryngoscope. Illustrated. \$1.00  
 James, Sore Throat, Its Varieties and Treatment.  
 Fourth Edition. Illus. \$1.25  
 ———, Laryngoscopy and Rhinoscopy. Third Edition.  
 Illustrated. \$2.00  
 Mackenzie, The Throat and Nose. Author's Edition.  
 With Original Plates. Volume I ready. 112 Illustrations.  
 Cloth \$4.00; Sheep \$5.00  
 Volume II. [In Press.]  
 ———, Diphtheria.  
 ———, Growths in the Larynx. \$2.00  
 ———, Pharmacopœia. Fourth Edition. \$1.25  
 Thompson, Coughs and Colds. .60

THERAPEUTICS.

(See also *Materia Medica and Action of Medicine.*)

- Kidd, The Laws of Therapeutics. Pap., .75; Cl. \$1.25  
 Kirby, On Phosphorus. Fifth Edition. \$1.00  
 Kane, Drugs That Enslave. The Opium, Chloral and  
 Other Habits. Illustrated. \$1.50  
 Mays, The Therapeutic Forces. \$1.25  
 Waring, Practical Therapeutics. A Text-book.  
 Third Edition. Cloth, \$4.00; sheep, \$5.00

URINE AND URINARY ORGANS.

- Acton, On the Reproductive Organs. Fourth Ed. \$2.50  
 Black, Renal, Urinary and Reproductive Organs. \$1.25  
 Beale, Illustrations of One Hundred Urinary Deposits.  
 On two Sheets. Each \$1.00; or, Mounted, \$1.25  
 Curling, On the Testis, Spermatic Cord and Scrotum.  
 Fourth Edition. Illustrated. \$5.50  
 Coulson, The Bladder and Prostate Gland. Sixth  
 Edition. Illustrated. \$6.40  
 Gant, The Bladder, Prostate Gland and Urethra.  
 Fourth Edition. Illustrated. \$3.00  
 Hoff, Hæmaturia. Illustrated. .75  
 Legg, The Examination of the Urine. Illustrated.  
 Fifth Edition. .75  
 Marshall & Smith, Chemical Analysis of the Urine.  
 Illustrated. \$1.00  
 Thompson, Diseases of the Urinary Organs. Sixth  
 London Edition. Illus. Paper, .75; cloth, \$1.25  
 ———, On Calculous Disease. Second Ed. \$1.00  
 ———, Lithotomy and Lithotrity. 3d Ed. \$3.50  
 ———, Diseases of the Prostate. 5th Ed. \$1.25  
 Tyson, Examination of Urine. Illus. 4th Ed. \$1.50  
 Thudichum, Pathology of the Urine, and Complete  
 Guide to Analysis. Second Edition. Illus. \$5.00

CLASSIFIED LIST.

Whittaker, Student's Primer on the Urine. II. \$1.50

VENEREAL DISEASES.

Durkee, On Gonorrhœa and Syphilis. 6th Ed. II. \$3.50

Lewen, The Treatment of Syphilis. Illustrated. \$1.25

VISITING LIST.

Lindsay & Blakiston's Physician's Visiting List,  
Published Annually.

SIZES AND PRICES.

For 25 Patients weekly.	Tucks, pockets, etc.,	\$1.00
50 " " "	" " "	1.25
75 " " "	" " "	1.50
100 " " "	" " "	2.00
50 " " " 2 Vols.	{ Jan. to June }	2.50
	{ July to Dec. }	
100 " " " 2 Vols.	{ Jan. to June }	3.00
	{ July to Dec. }	

INTERLEAVED EDITION.

For 25 Patients weekly, interleaved, tucks, etc.	1.25
50 " " "	1.50
50 " " " 2 Vols.	{ Jan. to June }
	{ July to Dec. }
	3.00

WATER.

Ekin, Potable Water. Second Edition. .75

Fox, Examination of Water, Air and Food. II. \$4.00

Frankland, Water Analysis. Illustrated. \$1.00

Mac Donald, Microscopical Analysis of. Illus. \$2.75

WOMEN, DISEASES OF.

Agnew, Female Perineum. Illustrated. \$1.25

Atthill, Diseases of Women. Fifth Edition. \$1.25

Aveling, Posture in Gynæcology and Other Operations. Illustrated. \$2.00

Byford, Diseases of Women. Third Edition. Illustrated. Cloth, \$5.00; sheep, \$6.00

—, On the Uterus. Illustrated. \$2.50

Courty, on the Uterus, Ovaries and Fallopian Tubes, 431 Illustrations. Cloth, \$6.00; leather, \$7.00

Dillnberger, Diseases of Women and Children. \$1.50

Gallabin, Guide to the Diseases of Women. II. \$1.25

Hewitt, Text-book of the Diseases of Women. Fourth Edition. Illustrated. Paper, \$1.50; cloth, \$3.50

Hodge, H. Lennox, Note-book for Cases of Ovarian Tumors. Diagrams. .50

—, Hugh L., Feticide. Cloth, .50; paper, .30

Smith, Heywood, Practical Gynaecology. Illus. \$1.25

—, Dysmenorrhœa. \$1.75

Savage, Surgery and Surgical Pathology of the Female Pelvic Organs. Colored Plates. \$12.00

Scanzoni, Diseases of Women. \$5.00

Tilt, The Change of Life in Women. Third Ed. \$1.25

—, Uterine Therapeutics and the Diseases of Women. Fourth London Edition. \$3.50

West, The Diseases of Women. Fourth Edition, Rewritten, Edited by Matthews Duncan. \$5.00

Any book in this catalogue may be obtained through the Booksellers, or will be sent, postpaid, upon receipt of the price, by the publishers.



# PHYSICIAN'S VISITING LIST.

(LINDSAY & BLAKISTON'S.)

*Thirty-second Year of its Publication.*

Containing Calendar, List of Poisons and Antidotes, Posological Tables, Marshall Hall's Ready Method in Asphyxia, List of New Remedies, Diagram of the Chest, etc.

## SIZES AND PRICES (with Dates).

For 25 Patients weekly.	Tucks, pockets, etc.,	\$1.00
50 " " "	" " "	1.25
75 " " "	" " "	1.50
100 " " "	" " "	2.00
50 " " 2 Vols.	{ Jan. to June }	2.50
	{ July to Dec. }	
100 " " 2 Vols.	{ Jan. to June }	3.00
	{ July to Dec. }	

## INTERLEAVED EDITION.

For 25 Patients weekly.	Interleaved, tucks, etc.,	1.25
50 " " "	" " "	1.50
50 " " 2 Vols.	{ Jan. to June }	3.00
	{ July to Dec. }	

*Perpetual Edition, without dates, size of the 25 Patients Interleaved, \$1.25.*

"It is certainly the most popular Visiting List extant."—*N. Y. Medical Journal.*

"Its compact size, convenience of arrangement, durability, and neatness of manufacture have everywhere obtained for it a preference."—*Canada Lancet.*

"For completeness, compactness, and simplicity of arrangement it is excelled by none in the market."—*New York Medical Record.*

"The book is convenient in form, not too bulky, and in every respect the very best Visiting List published."—*Canada Medical and Surgical Journal.*

"After all the trials made, there are none superior to it."—*Gaillard's Medical Journal.*

"It has become *Standard.*"—*Southern Clinic.*

"Its intrinsic value is a sufficient introduction wherever it is presented."—*American Medical Journal.*

"Regular as the seasons comes this old favorite."—*Michigan Medical News.*

"It is quite convenient for the pocket, and possesses every desirable quality."—*Medical Herald.*

"The most popular Visiting List extant."—*Buffalo Medical and Surgical Journal.*

"We have used it for years, and do not hesitate to pronounce it equal, if not superior, to any."—*Southern Clinic.*

"This Visiting List is too well known to require either description or commendation from us."—*Cinn. Med. News.*

— Sent by mail, postpaid, to any address, upon receipt of the price; or can be had through any bookseller in the United States or Canada.

P. BLAKISTON, SON & CO., Publishers,  
1012 Walnut Street, Philadelphia.

## Valuable Books Lately Published.

### DAY ON CHILDREN.

A Practical and Systematic Treatise on the Diseases of Children, for Practitioners and Students. By Wm. Henry Day, M.D. (author of "Headaches, their Causes and Cure). SECOND EDITION, REWRITTEN AND ENLARGED. Octavo.

Price, cloth, \$5.00; leather, \$6.00.

A careful examination of this book leads us to characterize it as a plain, straightforward treatise upon the subject upon which it treats, . . . giving sound practical advice."—*Philadelphia Medical Times*.

### Mackenzie on the Throat and Nose.

Diseases of the Throat and Nose, including the Pharynx, Larynx, Trachea, Esophagus, Nasal Cavities and Neck. By Morrell Mackenzie, M.D. 112 Illustrations. ONLY AUTHORIZED EDITION. Vol. I. Octavo. Price, cloth, \$4.00; leather, \$5.00.

Vol. II. *Nearly Ready*.

This edition contains the author's work on Diphtheria, formerly published separately.

"There can be but one verdict of the profession on this manual—it stands without any competitor in medical literature, as a standard work on the organs it professes to treat of."—*Dublin Medical Journal*.

### HARLEY ON THE LIVER.

Diseases of the Liver; with and without Jaundice. By George Harley, M.D., F.R.S. With colored plates and thirty-six wood-cuts. Bound in Heavy Cloth, Beveled Edges, \$5.00; Leather, with Raised Bands, \$6.00.

\*The author in his preface calls special attention to his sections on treatment, and the special chapter entitled "Hints on Diagnosis."

**P. BLAKISTON, SON & CO., Publishers,**  
1012 Walnut Street, Philadelphia.

# ON SLIGHT AILMENTS; Their Nature and Treatment.

By LIONEL S. BEALE, M.D., F.R.S.,

Professor of the Practice of Medicine at King's  
College, London.

Second Revised Edition, Enlarged and Illus-  
trated. Octavo. 283 Pages.

Strong Paper Covers, 75 cents. Cloth, \$1.25.

\*.\* This work is founded upon the author's introductory lectures to his students at King's College, London, and embraces much information concerning the diseases that, as a rule, are either overlooked or treated of very meagerly in the text-books, besides many ailments which, though slight themselves, often lead to dangerous results. As an introduction to the Practice of Medicine for students, the work will be found to serve an excellent purpose, and for the physician, especially the young practitioner, it has peculiar advantages. The style is clear, and the diagnosis and treatment accurate. It has been uniformly recommended by the Profession and Press.

SHORT OUTLINE OF CONTENTS.—Introductory. The Tongue in Health and Slight Ailments. Appetite. Nausea. Thirst. Hunger. Indigestion, its Nature and Treatment. Constipation, its Treatment. Diarrhoea. Intestinal Worms. Vertigo. Giddiness. Biliousness. Sick Headache. Drowsiness. Wakefulness, etc. Neuralgia. Rheumatism. Catching Cold, etc. The Feverish and Inflammatory State. Of the Actual Changes in Fever and Inflammation. Common Forms of Slight Inflammation, etc. Changes preparatory to the occurrence of disease. Concluding Remarks.

## PRESS NOTICES.

"We venture to say, that among the numerous medical publications, there has been none which will prove more useful to the young general practitioner, for whom it is really intended, than this volume, while the time of the older physician might be more unprofitably spent."—*American Journal of Medical Science.*

"It would be impossible within the space of a brief notice to do justice to a work so full of practical suggestions as we find this to be. Its trifling cost is no indication whatever of its intrinsic value, and those who read it will get the opinions and experience of a man whose knowledge has not stopped with the natural history of disease, but extends to its careful treatment."—*New Remedies.*


"We unhesitatingly recommend this work to every physician."—*New Orleans Medical and Surgical Journal.*

"It occupies a field not exactly filled by any other work with which we are familiar."—*Columbus Medical Journal.*

"We venture to say that there are few books which will prove more useful to the young general practitioner, for whom it is more especially intended, than this able, practical work of Dr. Beale."—*Buffalo Medical and Surgical Journal.*

**P. BLAKISTON, SON & CO., Publishers,**  
1012 Walnut Street, Philadelphia.







# BIDDLE'S

LANE MEDICAL LIBRARY

This book should be returned on or before  
the date last stamped below.

Recomm  
Colleg  
C

BIDDLE  
and I  
Profes  
Philad  
in ma  
Assist  
M.D.  
last r

Bou

"It will  
under the i  
*ical Journ*

"In shor  
be discusse  
*News.*

"In trutl

"Nothin  
disease are  
shapely for  
*can Practi*

"Biddle  
ard text-bo

"It cont  
and furnish  
*Canada L*

"The ne  
proof of the  
*ical Report*

"The sta  
is Biddle's.

"The larger works usually recommended as text-books in our medical schools are too voluminous for convenient use. This work will be found to contain in a condensed form all that is most valuable, and will supply students with a reliable guide."—*Chicago Medical Journal.*

\*.\* This Ninth Edition contains all the additions and changes in the U. S. Pharmacopœia, Sixth Revision.

**P. BLAKISTON, SON & CO., Publishers and Booksellers,  
1012 WALNUT STREET, PHILADELPHIA.**





